

# Xanthogranulomatous salpingitis and oophoritis associated with endometriosis and uterine leiomyoma presenting as intestinal obstruction

Prabath K. Abeysundara, Goluhewage S. Padumadasa, Warnakulasooriya G. M. Tissera and Prasantha S. Wijesinghe

*Department of Obstetrics and Gynaecology, Faculty of Medicine, University of Kelaniya, Ragama, Sri Lanka*

## Abstract

Xanthogranulomatous inflammation is a rare form of chronic granulomatous inflammation. Bacterial infections, immunosuppression, chronic inflammatory conditions, luminal obstruction, endometriosis, leiomyoma, abnormal lipid metabolism, ineffective antibiotic therapy, ineffective clearance of bacteria by phagocytes and chronic irritation of the urachal remnant have been implicated in the pathogenesis. There are very few reported cases of xanthogranulomatous salpingitis and oophoritis. We present such a case in a 34-year-old female, with primary subfertility for eight years, endometriosis, uterine leiomyoma, type II diabetes mellitus and a history of surgery for endometriosis and fibroids and surgical wound infection, who presented with symptoms of intestinal obstruction. The patient underwent emergency laparotomy followed by total abdominal hysterectomy and bilateral salpingo-oophorectomy. Histology revealed xanthogranulomatous salpingitis and oophoritis. Chronic inflammation due to inadequate treatment of bacterial infection, coupled with pelvic endometriosis and uterine leiomyoma may have led to xanthogranulomatous salpingitis and oophoritis.

**Key words:** endometriosis, leiomyoma, oophoritis, salpingitis, xanthogranulomatous.

## Introduction

Xanthogranulomatous inflammation is a rare form of chronic granulomatous inflammation, which causes tissue destruction and distortion of the affected organ. It is characterized by the presence of varying amounts of lipid laden foamy histiocytes, mononuclear cells, neutrophils, plasma cells, fibroblasts, marked fibrosis, foci of necrosis, parenchymal destruction and sometimes multinucleated giant cells.<sup>1-5</sup> Etiology and pathogenesis of this condition are not well understood. Several organs have been reported to be affected by xanthogranulomatous inflammation, most commonly the kidney followed by the gall bladder.<sup>1,6,7</sup> There are few reported cases of xanthogranulomatous salpingitis

and oophoritis.<sup>8,9</sup> We report a rare case of xanthogranulomatous salpingitis and oophoritis associated with endometriosis and uterine leiomyoma, presenting as intestinal obstruction.

## Case Report

A 34-year-old female with primary subfertility for eight years and type II diabetes mellitus presented with symptoms of intestinal obstruction. On examination, she was afebrile, her pulse rate was 88 bpm, blood pressure was 110/70 mmHg and abdomen was distended. Ultrasound scan revealed multiple fibroids, bilateral endometriomas and evidence of intestinal obstruction. She underwent an emergency laparotomy.

Received: September 27 2011.

Accepted: November 25 2011.

Reprint request to: Dr Prabath K. Abeysundara, Department of Obstetrics and Gynaecology, Faculty of Medicine, University of Kelaniya, PO Box 06, Thalagolla Road, Ragama, Sri Lanka. Email: heshanprabathkularathne@yahoo.com

Both small and large intestines were distended due to mechanical obstruction at the level of entry to the pelvis. The appendix was inflamed. Multiple adhesions between pelvic organs and the anterior abdominal wall were noted. The uterus was enlarged with multiple fibroids. The left ovary was enlarged to 10 × 10 cm, which was compressing the sigmoid colon. The right ovary, which contained a 2 × 2-cm cyst was adherent to the uterus. Both fallopian tubes were edematous and thickened. Multiple endometriotic patches were found all over the pelvic peritoneum. Adhesions were separated and total abdominal hysterectomy and bilateral salpingo-oophorectomy and appendectomy were performed. Swabs, which were taken for culture during surgery, showed a mixed growth of coliform organisms and *Pseudomonas*. Urine and blood cultures were negative. The patient was treated with metronidazole and levofloxacin for seven days. Her postoperative period was uncomplicated.

Five years earlier, the patient had undergone surgery for endometriosis and uterine fibroids. Subsequently she developed an incisional hernia, which was surgically repaired. This was complicated by wound infection and abscess formation around the umbilicus, necessitating surgical exploration and drainage. Pus culture revealed a coliform growth. She was treated with intravenous ciprofloxacin and metronidazole for four days and discharged on oral antibiotics for one week duration.

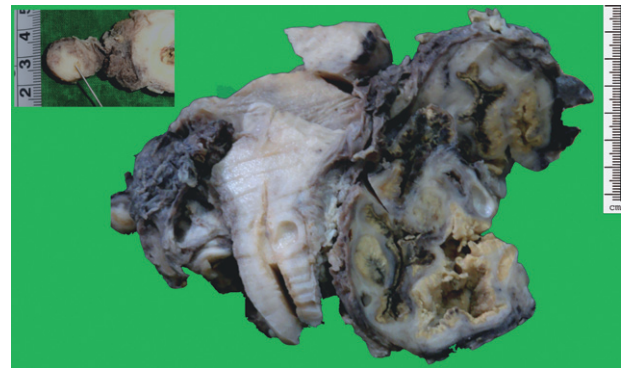
## Histopathological findings

### Macroscopy

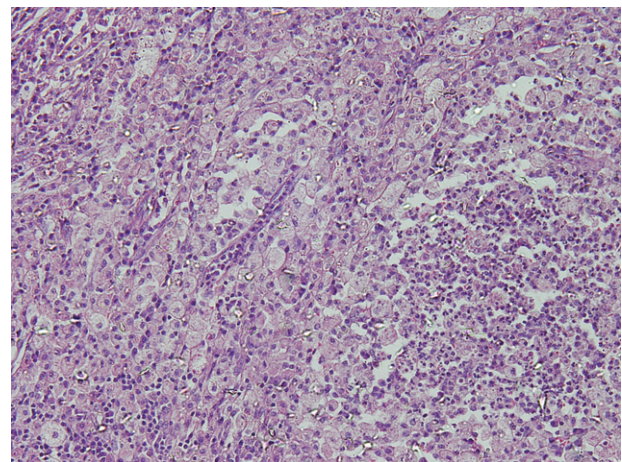
The uterus measured 12 × 6 × 5 cm. There were bilateral ovarian masses. The myometrium contained multiple nodules ranging from 0.7 to 3.5 cm. The left ovarian mass was 11 × 6 × 5 cm. The cut surface showed an irregular cystic area lined by a thick, friable, yellowish inner lining. The right ovarian mass measured 4 × 3 × 2.5 cm. The cut surface showed a cystic lesion similar to that described above in the other ovary. Both fallopian tubes appeared thickened (Fig. 1). The appendix appeared thickened.

### Microscopy

Mass forming cystic lesion in both ovaries showed sheets of foamy macrophages admixed with lymphocytes and plasma cells. Patchy collections of neutrophils were also noted. There was no evidence of a neoplasm. Both fallopian tubes showed focal flattening of plicate with chronic inflammation in subepithelial



**Figure 1** Coronal section of the uterus and ovaries. The ovarian mass shows irregular cystic areas lined by a thick friable yellowish material. Inset: pointer shows thickened fallopian tube.



**Figure 2** Histology of the tubo-ovarian masses shows sheets of foamy macrophages admixed with lymphocytes and plasma cells with patchy collections of neutrophils (HE ×200).

tissue. Features were compatible with xanthogranulomatous salpingitis and oophoritis (Fig. 2). The cervix and the endometrium were unremarkable. The myometrium showed leiomyomas. Histology revealed periappendicitis, probably due to adjacent pelvic inflammation.

## Discussion

There are several suggested etiologies of xanthogranulomatous inflammation. Among them are bacterial infections, immunosuppression, chronic inflammatory conditions, luminal obstruction, endometriosis, leiomyomas, abnormal lipid metabolism, ineffective

antibiotic therapy, ineffective clearance of bacteria by phagocytes and chronic irritation of the urachal remnant.<sup>1,6,8,10-12</sup> Associated microorganisms include *Escherichia coli*, *Pseudomonas aeruginosa*, *Proteus vulgaris*, *Bacteroides fragilis*, *Salmonella typhi*, *Actinomyces species*, *Streptococcus (Enterococcus) faecalis*, *Staphylococcus aureus*, *Streptococcus viridans*, *Torulopsis (Candida) glabrata*, and group B streptococci. *Escherichia coli* is the commonest isolated organism.<sup>8,10</sup> Xanthogranulomatous salpingitis and oophoritis mimic ovarian malignancy, which poses diagnostic difficulties.<sup>13</sup> Evidence suggests that it is not a premalignant condition.<sup>6</sup>

Endometriomata contain altered blood and shed endometrium. This is a potential site for bacterial infections. In our case a mixed growth of coliform organisms and *Pseudomonas* were found. Long-standing endometriomata could have led to infection in the ovaries. Inadequate antibiotic therapy for sepsis following incisional hernia repair in our patient may have led to xanthogranulomatous salpingitis and oophoritis. Uterine fibroids also may have predisposed to infection.<sup>1</sup> Our patient had recurrent fibroids. Diabetes mellitus would have been a contributory factor.

Coliform organisms and *Pseudomonas* are normal flora of the lower gastrointestinal tract. There were endometriotic patches involving bowel as noted at the time of laparotomy. Endometriosis involving the intestinal wall would predispose to infection of the endometriomata.

Another possibility was spreading of the infection from the anterior abdominal wall abscess, which complicated the incisional hernia repair. Coliform organisms, which were isolated from the anterior abdominal wall abscess, were also found in association with the subsequent pelvic pathology. Xanthogranulomatous inflammation usually affects the dome of the bladder and is associated with an urachal remnant.<sup>9</sup> It is possible for infection to spread from the abscess through the urachal remnant to the dome of the bladder and endometriomata.

Chronic inflammation due to inadequate treatment of bacterial infection following incisional hernia repair, coupled with pelvic endometriosis and uterine leiomyoma may have led to xanthogranulomatous salpingitis and oophoritis in this patient. Long-standing diabetes mellitus in our patient may have been a contributory factor. In view of multiple fibroids, the gross distortion of the ovaries and the fallopian tubes due to chronic inflammation, and fibrosis causing intestinal obstruction, our patient was treated with total abdominal hysterectomy and bilateral salpingo-oophorectomy.

## Acknowledgments

We thank Dr BAGG Mahendra, Consultant Histopathologist of the Department of Pathology, Faculty of Medicine, University of Kelaniya for the histopathological analysis of the case.

## Disclosure

No author has any potential conflict of interest. No benefits in any form have been received or will be received from any commercial party related directly or indirectly to the subject of this article.

## References

1. Howey JM, Mahe E, Radhi J. Xanthogranulomatous salpingitis associated with a large uterine leiomyoma. *Case Report Med* 2010; **2010**: 970805. Epub 2010 Oct 17.
2. Duarte RL, de Lima MM, de Carvalho M, da Silva GB, De Francesco E. Emphysematous and xanthogranulomatous pyelonephritis: Rare diagnosis. *Braz J Infect Dis* 2010; **14**: 374–376.
3. Kim HS, Joo M, Chang SH *et al*. Xanthogranulomatous pancreatitis presents as a solid tumor mass: A Case report. *J Korean Med Sci* 2011; **26**: 583–586.
4. Guarino M, Reale D, Micoli G, Tricomi P, Cristofori E. Xanthogranulomatous gastritis: Association with xanthogranulomatous cholecystitis. *Clin Pathol* 1993; **46**: 88–90.
5. Mark ES, Michael TM, Robert JK. Benign disease of the endometrium. In: Robert JK (ed.). *Blaustein's Pathology of the Female Genital Tract*. New York: Springer, 2002; 421–426.
6. Ghosh M, Sakhuja P, Agarwal AK. Xanthogranulomatous cholecystitis: A premalignant condition? *Hepatobiliary Pancreat Dis Int* 2011; **10**: 179–184.
7. Ranadive NU, Abhyankar SC, Hodarkar RD, Bapat SD, Deodhar KP. Xanthogranulomatous pyelonephritis-study of 14 cases. *J Postgrad Med* 1986; **32**: 158–160.
8. Jung SE, Lee JM, Lee KY, Han KT, Hahn ST. Xanthogranulomatous oophoritis – MR imaging findings with pathologic correlation. *AJR* 2002; **178**: 749–751.
9. Gray Y, Libbey NP. Xanthogranulomatous salpingitis and oophoritis – A case report and review of the literature. *Arch Pathol Lab Med* 2001; **125**: 260–263.
10. Chung DE, Carr LK, Sugar L, Hladunewich M, Deane LA. Xanthogranulomatous cystitis associated with inflammatory bowel disease. *Can Urol Assoc J* 2010; **4**: E91–E93.
11. Shukla S, Pujani M, Singh SK, Pujani M. Xanthogranulomatous oophoritis associated with primary infertility and endometriosis. *Indian J Pathol Microbiol* 2010; **53**: 197–198.
12. Yener N, Ilter E, Midi A. Xanthogranulomatous salpingitis as a rare pathologic aspect of chronic active pelvic inflammatory disease. *Indian J Pathol Microbiol* 2011; **54**: 141–143.
13. Philip BC. Nonneoplastic lesions of the ovary. In: Robert JK (ed.). *Blaustein's Pathology of the Female Genital Tract*. New York: Springer, 2002; 675–719.