

Umbilical endometriosis-A simple but challenging diagnosis for surgeons

K.G.H. Jayathilake¹, S. Withana¹, R. Siriwardane¹, G. Mahendra², C. Liyanage¹

1 Department of Surgery, Faculty of Medicine, University of Kelaniya, Sri Lanka.

2 Department of Pathology, Faculty of Medicine, University of Kelaniya, Sri Lanka.

Keywords: Umbilical; endometriosis; umbilical lump; extrapelvic endometriosis

Introduction

Endometriosis is a challenging but common gynaecological condition which is characterized by the presence of endometrial glands and stroma outside the uterus [1]. It presents mainly with involvement of the pelvic organs. Extrapelvic presentations in almost all parts of the body have been reported and account for about one percent of the total cases [1]. However, spontaneous umbilical endometriosis nodules or endometriosis secondary to surgery accounts for only 0.5% to 1% of all endometriosis cases [2].

Case presentation

A 49 year-old parous woman who presented with an umbilical lump for two years complained of cyclical monthly pain and bluish discolouration. There was no history of bleeding or discharge from the site. She had undergone laparoscopic hysterectomy and left sided salpingo-oophorectomy four years back due to endometriosis causing severe dysmenorrhea.

At the time of presentation she had a 1 × 1.5 cm purplish nodule at the umbilicus (Figure 1). It was not tender and there were no signs of infection. There was a 1cm well healed surgical scar below the umbilicus.

Fine needle aspiration cytology of the umbilical nodule confirmed the diagnosis as endometriosis at the umbilicus. Following a discussion with the patient and clear explanation about the possibility of recurrence and the need to remove the umbilicus, the nodule was completely excised with the umbilicus and the defect was repaired. As the patient was not concerned about the cosmetic outcome, umbilical reconstruction was not

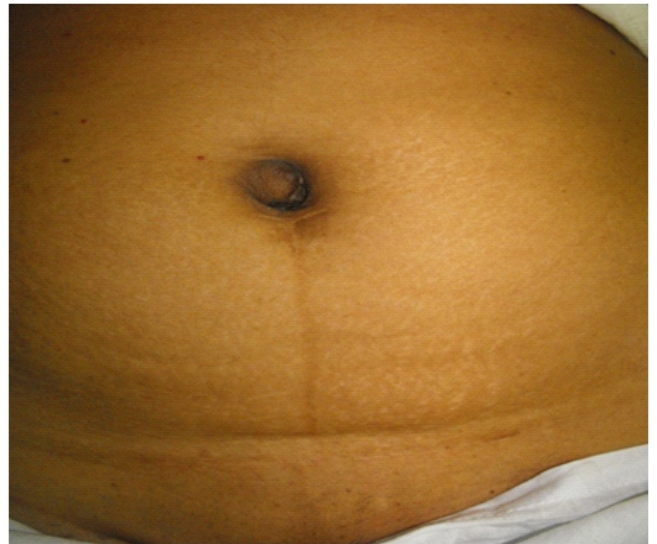

Figure 1. Umbilical lump with bluish discolouration.

carried out. The histology confirmed the diagnosis of endometriosis (Figure 2).

Discussion

Umbilical endometriosis can be primary or secondary to a surgical scar. Villar, in 1886, reported the first case of umbilical endometriosis. Hence, this condition is also called Villar's nodule [1]. Similar to our own case umbilical endometriosis at the site of the laparoscopic entry is one of the commonest. The primary umbilical endometriosis is known to be associated with severe pelvic endometriosis compared to those with scar endometriosis [3].

In this patient, cyclical pain with a classical purplish nodule clinched the diagnosis; but clinical diagnosis of umbilical endometriosis is, at times, difficult with varying presentations in colour, character of pain and size. Hence, malignant melanoma, paraumbilical hernia, granuloma, primary or metastatic adenocarcinoma (Sister Joseph nodule), nodular melanoma, and cutaneous endosalpingosis should be considered.

Correspondence: K.G.H. Jayathilake
E-mail: g.hiroshi@yahoo.com

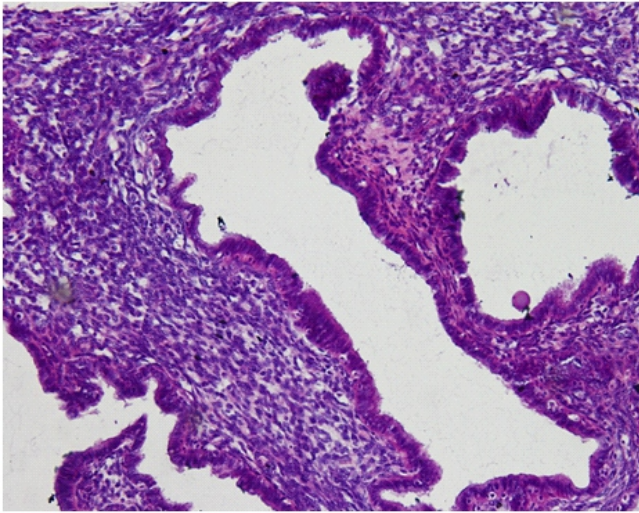


Figure 2. Haematoxylin and eosin section (20x10) showing tortuous glands surrounded by dense cellular stroma lying in a collagenous background. The glands are lined by tall columnar epithelium that resembles the endometrial glandular epithelium. The sub-epithelium is composed of small round cells that resemble the endometrial stroma.

Surgical excision is the treatment of choice for this condition. If a wide excision and complete removal of the umbilicus is anticipated, it should be discussed with the patient, and reconstruction of the umbilicus can be offered [4].

In our patient, endometriosis was previously diagnosed and treated by hysterectomy and left sided salpingo-oophorectomy. However, in a newly diagnosed similar case the chances of coexisting pelvic endometriosis should be sought and treated with special concern for fertility. Pelvic endometriosis is a common condition, but the diagnosis of primary umbilical endometriosis requires a high degree of suspicion.

References

1. Sreelakshmi K, Muralidhar V P, Mary M; Umbilical laparoscopic scar endometriosis. *J Hum Reprod Sci.* 2011 Sep-Dec; 4(3): 150–152.
2. Latcher JW; Endometriosis of the umbilicus. *Am J Obstet Gynecol.* 1953;66:161–8.
3. Agarwal A, Fong Y F; Cutaneous endometriosis, *Singapore Med J* 2008; 49(9): 704-709
4. Bagade P, Guirgus MM; Menstruating from the umbilicus as a rare case of primary umbilical endometriosis: A case report. *J Med Case Reports.* 2009;3:9326

Key points:

- Umbilical endometriosis can be primary or secondary to a surgical scar.
- malignant melanoma, paraumbilical hernia, granuloma, primary or metastatic adenocarcinoma (Sister Joseph nodule), nodular melanoma and cutaneous endosalpingosis should be considered in the differential diagnosis.
- Surgical excision and reconstruction of the umbilicus is the treatment of choice.