

# Attempted one anastomosis gastric bypass converted to a sleeve gastrectomy in an adult patient with asymptomatic intestinal malrotation: A case report

SAGE Open Medical Case Reports  
Volume 12: 1–4  
© The Author(s) 2024  
Article reuse guidelines:  
sagepub.com/journals-permissions  
DOI: 10.1177/2050313X241263445  
journals.sagepub.com/home/sco



Umesh Jayarajah<sup>1</sup> , Kalaiyukan Sathasivam<sup>1</sup>, Sumudu Kumara<sup>2</sup>  
and Thejana Wijeratne<sup>1,3</sup>

## Abstract

Unexpected encounters during surgery for obesity such as midgut malrotation cause specific technical challenges to the surgeon. We present a rare case of asymptomatic complete intestinal malrotation midway during a one anastomosis gastric bypass procedure. A 62-year-old male with a body mass index of 49 kg/m<sup>2</sup> and metabolic syndrome was planned for one anastomosis gastric bypass. A gastric tube was created along the lesser curvature. During the attempt to identify the suitable small bowel loop, an unexpected completely malrotated gut was noted. Due to the intraoperative difficulty in identifying the correct loop to anastomose to the gastric tube an intraoperative decision was taken to convert the procedure to a sleeve gastrectomy. The created gastric tube was re-anastomosed to distal stomach, and the redundant stomach was resected. Postoperative recovery was uneventful, and weight loss was satisfactory. Attempted one anastomosis gastric bypass converted to a sleeve gastrectomy was a successful bailout procedure.

## Keywords

One anastomosis gastric bypass, sleeve gastrectomy, bariatric surgery, intestinal malrotation, case report

Date received: 29 October 2023; accepted: 3 June 2024

## Introduction

Intestinal malrotation is an anatomical anomaly of the positioning of the gastrointestinal tract and vessels. Postmortem studies suggest that the incidence of malrotation is 1 in 6000 live births.<sup>1</sup> Around 64%–80% of the malrotation cases present in the first month and 90% within the first year of life. Adult presentation is very rare and only 0.2%–0.5% of cases have been reported.<sup>2</sup> The prevalence of asymptomatic malrotation in adults is unknown.<sup>2</sup>

Previous reports have documented the detection of asymptomatic malrotation during gastric bypass surgery for obesity.<sup>3</sup> There are controversies regarding the proper treatment of asymptomatic patients in whom intestinal malrotation was encountered incidentally during operation for another indication. This is because the risks of the corrective procedures is not objectively known to weigh the risk versus benefit of the corrective procedure.<sup>4</sup> However, it has been shown that these patients can safely undergo bariatric surgery laparoscopically, with a few instances of procedure modification being required.<sup>5,6</sup>

Unexpected encounters during surgery for obesity such as midgut malrotation cause specific diagnostic and technical challenges to the operating surgeon. The surgeon may have performed certain irreversible steps and, therefore, may have to modify the procedure to suite the patient's anatomy.<sup>7</sup> In obese patients, further challenges due to limited retraction, excess fat, and limited visualization may be encountered. Thus, it is mandatory for surgeons to anticipate such challenges and be ready with possible bail out options in case of such encounters.<sup>2</sup> We reported a rare case of unexpected

<sup>1</sup>Department of Surgery, Colombo South Teaching Hospital, Dehiwala, Sri Lanka

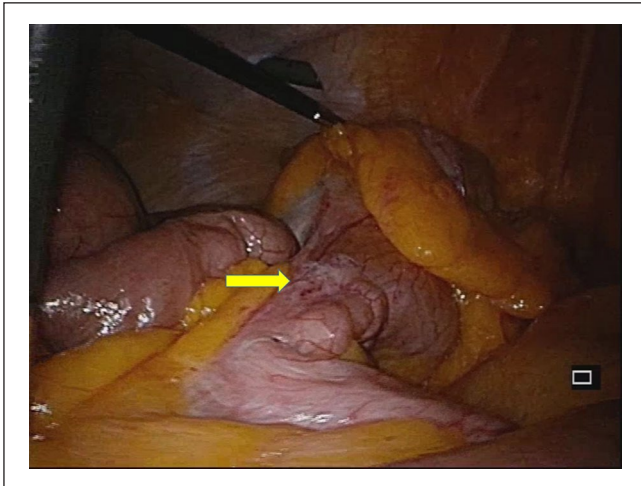
<sup>2</sup>Department of Surgery, Faculty of Medicine, University of Kelaniya, Kelaniya, Sri Lanka

<sup>3</sup>Department of Surgery, Faculty of Medical Sciences, University of Sri Jayawardanapura, Nugegoda, Sri Lanka

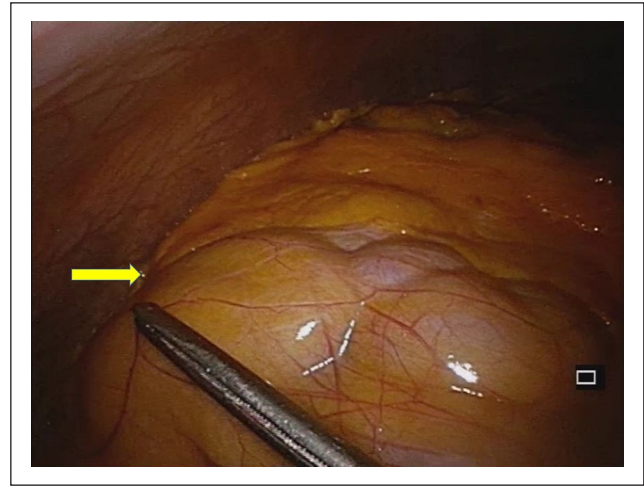
### Corresponding Author:

Umesh Jayarajah, University Surgical Unit, Colombo South Teaching Hospital, Dehiwala 10350, Sri Lanka.  
Email: umeshe.jaya@gmail.com





**Figure 1.** Image showing ileocaecal junction (yellow arrow) and caecum were found in the left iliac fossa.



**Figure 2.** Image showing the proximal small bowel was encased into a cocoon (yellow arrow) in the right iliac fossa region.

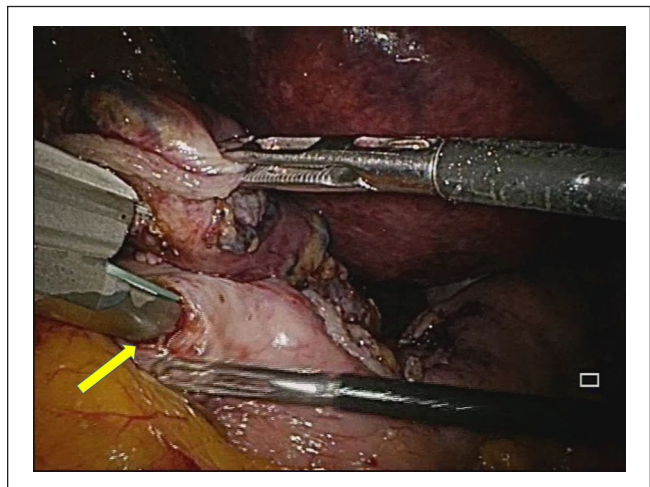
finding of complete intestinal malrotation in a 62-year-old male midway during a one anastomosis gastric bypass (OAGB) procedure for obesity.

### Case presentation

A 62-year-old male with hypertension, dyslipidemia, diabetes mellitus, and obstructive sleep apnoea was planned for a laparoscopic OAGB after routine workup. His body mass index was 49 kg/m<sup>2</sup>. His preoperative abdominal ultrasonography was normal, and upper gastrointestinal endoscopy was unremarkable expect for voluminous elongated stomach. Owing to the associated metabolic syndrome, a decision was made to perform a laparoscopic OAGB. A long stomach with adhesions to the bulky left hepatic lobe was noted. A gastric tube was created along the lesser curvature using laparoscopic endo-GIA staplers. During the attempt to identify the suitable small bowel loop, an unexpected completely malrotated gut was noted. The ileocaecal junction and caecum were found in the left iliac fossa (Figure 1), while the proximal small bowel was encased into a cocoon in the right iliac fossa region (Figure 2). Due to the intraoperative difficulty in identifying the correct loop to anastomose to the gastric tube an intraoperative decision was taken to convert the procedure to a sleeve gastrectomy.

The created gastric tube was re-anastomosed to distal stomach, and the redundant stomach along the greater curvature was resected (Figure 3). A side-to-side stapler anastomosis was performed, and the defect to accommodate the staplers were closed using 4/0 polydioxanone sutures. The redundant stomach was transected and excised using endo-GIA staplers (Figures 4 and 5).

Postoperatively, the patient had an uneventful recovery expect for superficial wound infection at the site of removal of specimen and has satisfactory weight loss. Weight loss



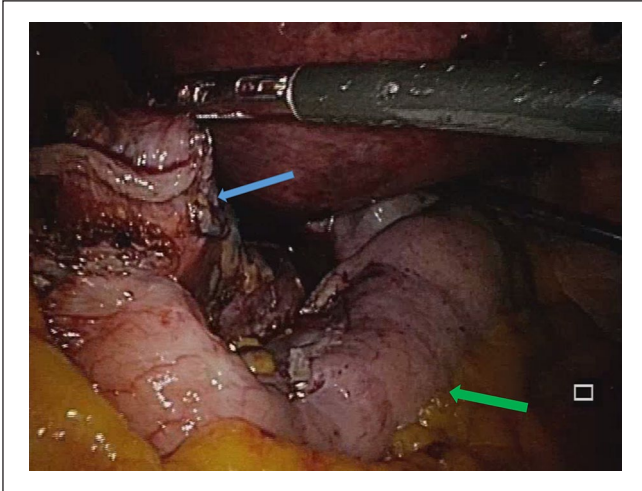
**Figure 3.** Anastomosis of created gastric tube to distal stomach using an endo-GIA stapler (yellow arrow).

was satisfactory (15 kg over 6 months) with better control of comorbidities.

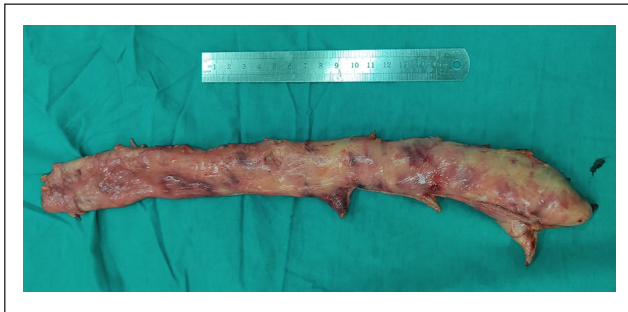### Discussion

Intestinal malrotation is a relatively rare congenital abnormality where the fetal midgut fails to proceed with its physiological rotation along the axis of superior mesenteric artery and usually results small bowels to locate in the right side of the abdomen and large intestine in the left side. The incidence of midgut malrotation among bariatric patients is 5 in 1183 (0.4%).<sup>2</sup>

A basic understanding of the intestinal embryology if essential to familiarize with anatomical aberrations associated with intestinal malrotation. During the sixth week of development of the fetus, due to slow expansion of the



**Figure 4.** Image showing the gastric sleeve (blue arrow) and the proposed remnant stomach (green arrow).



**Figure 5.** Image showing the resected specimen.

peritoneal cavity compared to the rapid lengthening of the midgut, physiological herniation of the primary loop of midgut occurs through the umbilicus.<sup>8</sup> During this process, the midgut undergoes 90° of counterclockwise rotation around the superior mesenteric artery. Few weeks later, the midgut returns into the peritoneal cavity, and further 180° of counterclockwise rotation around the superior mesenteric artery takes place. Depending on the affected stage, there are three types of malrotation described.<sup>8</sup>

In reverse rotation, the initial 90° of counterclockwise rotation takes place. Thereafter, a 180° of clockwise rotation occurs leading to a net 90° of clockwise rotation. This will result in retroperitoneal transverse colon which is located anterior to the superior mesenteric vessels and posterior to the distal part of the duodenum which is located intraperitoneally.<sup>8</sup> In the case of “nonrotation,” only the initial 90° of counterclockwise rotation takes. This will result in small intestine and large intestine to locate right and left sides of the peritoneal cavity, respectively, which is the likely cause in our patient.<sup>8</sup> Mixed rotation causes upper limb of the primary midgut loop to rotate 90° counterclockwise and distal

limb to rotate 180° counterclockwise. This will lead to fixity of the caecum in the midline usually just inferior to the pylorus of the stomach and positioning of the duodenum in the right side of the abdomen.<sup>8</sup>

OAGB and sleeve gastrectomy are commonly used surgical methods for obesity. OAGB is more efficient in controlling and remitting type 2 diabetes mellitus compared to sleeve gastrectomy. So in bariatric patients with metabolic syndrome, type 2 diabetes mellitus, the choice of the surgery is likely to be a gastric bypass procedure like a OAGB. In laparoscopic OAGB, small gastric pouch is created using linear stapling devices. Then a gastrojejunostomy is created between the gastric pouch and the jejunum usually more than 150 cm from the angle of Treitz. Presence of abnormally oriented small intestines will cause challenges to the surgeon as the anomaly is likely detected once the gastric tube has been already created, and the small bowel is inspected to identify the suitable loop for anastomosis. In such previously reported cases, anatomy was delineated laparoscopically or converted to open to complete the anastomosis.<sup>9</sup> However, open surgery in obese individuals carry its own morbidity. In our case, we could not identify the anatomy due to dense adhesions and difficulty in retraction and visualization in the obese abdomen. Therefore, an intraoperative decision was taken to reverse the procedure and bail out by converting to a sleeve gastrectomy. The patient had satisfactory postoperative outcome and weight reduction.

The presence of intestinal malrotation could have been identified if a diagnostic laparoscopy was performed prior to the creation of the gastric tube. Although this may be ideal, there is no definite guideline or protocol strictly recommending this practice. The measurement and inspection of the entire small bowel prior to an OAGB is not done by many. Therefore, we strongly recommend a diagnostic laparoscopy for measurement and inspection of the small bowel prior to proceeding with the creation of the gastric tube to minimize such mishaps.

## Conclusion

Midgut malrotation encountered in obesity surgery is a rare and challenging encounter for the surgeon. Unexpected encounters during surgery for obesity such as midgut malrotation cause specific diagnostic and technical challenges to the operating surgeon. The surgeon may have performed certain irreversible steps and, therefore, may have to modify the procedure to suite the patient’s anatomy. We report a rare case where conversion of the OAGB procedure to a sleeve gastrectomy was performed by anastomosing to the resected stomach which yielded successful outcomes. Furthermore, we strongly recommend a diagnostic laparoscopy for measurement and inspection of the small bowel prior to proceeding with the creation of the gastric tube to minimize such mishaps.

## Acknowledgements

None.

## Author contributions

U.J., K.S., S.K., and T.W. contributed to collection of information and writing of the manuscript. U.J. and T.W. contributed to writing and final approval of the manuscript. All authors read and approved the final version of the manuscript.

## Availability of data and material

All data generated or analyzed during this study are included in this published article.

## Declaration of conflicting interests

The author(s) declared no potential conflicts of interest with respect to the research, authorship, and/or publication of this article.

## Funding

The author(s) received no financial support for the research, authorship, and/or publication of this article.

## Ethics approval

Our institution does not require ethical approval for reporting individual cases or case series.

## Consent

Written informed consent was obtained from the patient for anonymized information and accompanying images to be published in this article. A copy of the written consent is available for review by the Editor-in-Chief of this journal on request.

## Research registration

Not applicable.

## ORCID iD

Umesh Jayarajah  <https://orcid.org/0000-0002-0398-5197>

## References

1. Salehi Karlslätt K, Husberg B, Ullberg U, et al. Intestinal malrotation in children: clinical presentation and outcomes. *Eur J Pediatr Surg* 2023; 34(3): 228–235.
2. Shockcor N, Nzara R, Pal A, et al. Operative approach to intestinal malrotation encountered during laparoscopic gastric bypass. *J Surg Case Rep* 2020; 2020(12): rjaa466.
3. Nicholas R, Mohammed S, Bascombe N, et al. Discordant intestinal malrotation in adult monozygotic twins discovered incidentally during laparoscopic gastric bypass: a case report and review of the literature. *Int J Surg Case Rep* 2022; 92: 106819.
4. Gibbs KE, Forrester GJ, Vemulapalli P, et al. Intestinal malrotation in a patient undergoing laparoscopic gastric bypass. *Obesity Surg* 2005; 15(5): 703.
5. Dan D, Bascombe N, Harnanan D, et al. Malrotation of the midgut in laparoscopic Roux-en-Y gastric bypass. *Zhonghua wei chang wai ke za zhi = Chin J Gastrointest Surg* 2010; 13(9): 678–80.
6. Vidal EA, Rendon FA, Zambrano TA, et al. Intestinal malrotation in patients undergoing bariatric surgery. *ABCD Arquivos Brasileiros de Cirurgia Digestiva (São Paulo)* 2016; 29: 24–26.
7. Ko G, Smith A, Cassie S, et al. Incidentally discovered intestinal nonrotation at time of bariatric surgery: which operation to perform? *Surg Obesity Relat Dis* 2019; 15(3): 424–430.
8. Haque S and Koren JP. Laparoscopic Roux-en-Y gastric bypass in patients with congenital malrotation. *Obes Surg* 2006; 16(9): 1252–1255.
9. Palepu RP, Harmon CM, Goldberg SP, et al. Intestinal malrotation discovered at the time of laparoscopic Roux-en-Y gastric bypass. *J Gastrointest Surg* 2007; 11(7): 898–902.