

# A rare case of synchronous hepatocellular and periampullary carcinoma

Perera WHN, Uragoda B

Colombo North Teaching Hospital, Ragama.

Correspondence to- Perera WHN, Colombo North Teaching Hospital, Ragama,  
E-mail: nayanatharaperera7@gmail.com

## Summary

Synchronous multiple primary tumours are a rare occurrence. We report a rare case of multiple primaries involving hepatobiliary system in which a 64-year-old male who was diagnosed with hepatocellular carcinoma and periampullary carcinoma.

**Keywords** - synchronous hepatocellular, periampullary carcinoma

## Introduction

Hepatocellular carcinoma is the primary malignancy of the liver and the fourth leading cause of cancer related deaths<sup>1</sup>. It predominantly occurs in patients with cirrhosis. Periampullary carcinoma is relatively uncommon and arises around ampulla of Vater, which accounts for 0.5 - 2% of gastrointestinal tumours. Multiple primary synchronous tumours are rare, and it is even rarer to have both tumours involving hepatobiliary system. Only two cases of synchronous hepatocellular and pancreatic carcinoma<sup>2,3</sup> and only one case of synchronous hepatocellular and ampullary carcinoma were reported in the literature<sup>4</sup>. Here, we report a rare case of synchronous hepatocellular and periampullary carcinoma.

## Case Report

67-year-old newly diagnosed Child -Pugh B cirrhotic male presented with low grade fever, loss of appetite, loss of weight and generalized pruritus developed a few months later. He has a history of diabetes mellites, hypertension, and chronic kidney disease. He was a heavy alcohol user and a non-smoker. There was no significant family history of cancer.

On examination, he was anicteric, pale and there were no signs of decompensated cirrhosis. There was a hard mass in right hypochondrium. His investigations revealed normal liver transaminase levels. Other investigations were as below.

Contrast Enhanced Computed Tomography (CECT) of the abdomen revealed a cirrhotic liver and a focal liver lesion (7x6cm) in segment VI/VII (Figure 1). The common bile duct was dilated (1.4cm), and there was an ill-defined focal area (2.3x2.1cm) in the periampullary region. Pancreatic duct was also dilated (5mm), and there was no pancreatic mass lesion. Magnetic Resonance

Cholangiopancreatography (MRCP) confirmed the above findings. In his upper gastric endoscopy, there were fundal varices and a suspicious lesion in the ampulla (Figure 2). Biopsies were taken from the lesion and it revealed a moderately differentiated adenocarcinoma.

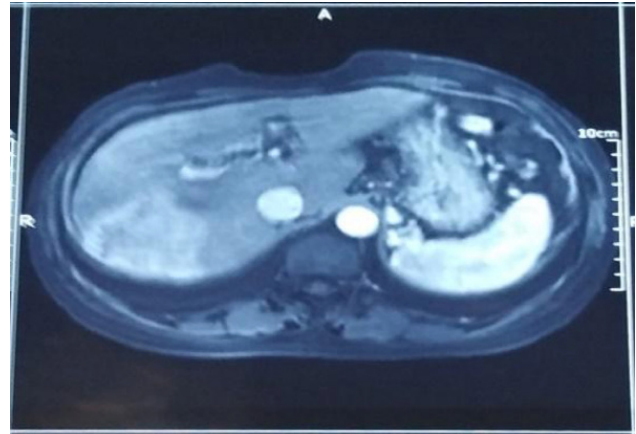


Figure 1: A metastatic deposit in the mesenteric border of the small bowel.

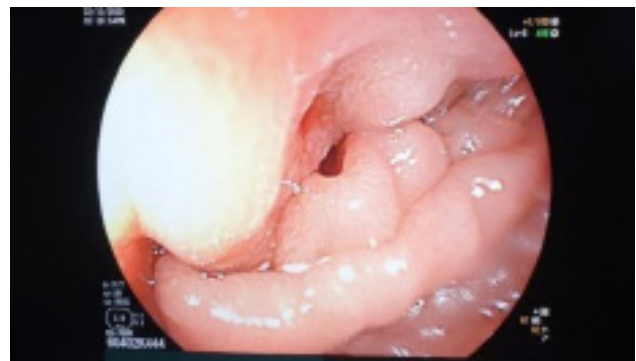

Figure 2- Endoscopic view of ampullary region

## Discussion

According to Warren and Gates criteria for multiple primary malignancies, each tumour must be histologically distinct and the probability of one being a metastasis of the other should be excluded<sup>5</sup>. Multiple primary malignancies can be synchronous or metachronous. Synchronous tumours are defined as ones that present simultaneously or within six months from the other. According to Surveillance, Epidemiology, and End Results (SEER) program, incidence of multiple primaries varies from 1% to 16%, depending on the first primary cancer. Higher incidences of synchronous cancers were reported with patients with primary malignancy in urinary bladder (16%), oral cavity & pharynx (15%) and uterus (11%). Synchronous tumours with liver primary are reported to be 1%<sup>6</sup>.

In this case, we are discussing about synchronous hepatocellular carcinoma with periampullary carcinoma. Only one case of synchronous hepatocellular carcinoma and ampullary carcinoma has been reported in the literature<sup>4</sup>.

CECT abdomen of this patient revealed arterial phase enhancement with portal venous phase washout in segment VI/VII lesion, which is a characteristic feature in hepatocellular carcinoma. Biopsy taken from the periampullary tumour was clearly suggestive of peri ampullary carcinoma.

Management of multiple primary malignancies is challenging and needs a multidisciplinary approach. Stage of the cancers at diagnosis, curability and suitable therapy without negative impact on the other cancer are limiting factors in the management. Periampullary carcinoma consists of tumours originating from the ampullary region. The standard surgical treatment option for ampullary carcinoma is pancreaticoduodenal resection (Whipple procedure). Treatment options for Hepatocellular carcinoma (HCC) depend on multiple factors. In this case, due to his medical comorbidities and Child B cirrhosis with portal hypertension, surgical management was not favoured for HCC. Transarterial Chemoembolization (TACE) was arranged for the segment VI/VII lesion. Considering the outcome of HCC after TACE and relative contraindication of performing Whipple surgery in the presence of background cirrhosis, endoscopic palliative stenting was done for the periampullary carcinoma.

### References

1. Yang, J. D., & Heimbach, J. K. (2020). New advances in the diagnosis and management of hepatocellular carcinoma. *The BMJ*. 2020;371:m3544.
2. Pan, P. Y., Lai, P. S., & Hsiao, C. Y. (2019). A Patient with Synchronous Primary Hepatocellular Carcinoma and Primary Pancreatic Ductal Adenocarcinoma. *Indian Journal of Surgery*, 2019;81(6):596–598.
3. Yadav, V., Panda, D., Patidar, Y., & Bihari, C. (2014). A rare case report: Carcinoma pancreas with hepatocellular carcinoma. *Indian Journal of Palliative Care*. 2014;20(1):53–56.
4. Davidson, M., Aioub, M., Gutierrez, M., Song, K., Hagopian, E., & Karpeh, M. (2017). Operable synchronous ampullary carcinoma and hepatocellular carcinoma: a case report and review of the literature. *Journal of Surgical Case Reports*, 2017;(9):1–3.
5. Warren, S., & Ehrenreich, T. (1944). Multiple Primary Malignant Tumors and Susceptibility to Cancer. *Cancer Research*, 1944;4(9):554–570
6. Hayat, M. J., Howlander, N., Reichman, M. E., & Edwards B., K. (2007). Cancer Statistics, Trends, and Multiple Primary Cancer Analyses from the Surveillance, epidemiology, and End Results (SEER) Program. *The Oncologist*. 2007;12(1):20-37