

**ORIGINAL ARTICLE**

# Characteristic dental pattern with hypodontia and short roots in Fraser syndrome

Felix Kunz<sup>1</sup> | Hülya Kayserili<sup>2</sup> | Alina Midro<sup>3</sup> | Deepthi de Silva<sup>4</sup> |  
Sriyani Basnayake<sup>5</sup> | Yeliz Güven<sup>6</sup> | Jan Borys<sup>7</sup> | Denny Schanze<sup>8</sup> |  
Angelika Stellzig-Eisenhauer<sup>1</sup> | Agnes Bloch-Zupan<sup>9,10,11</sup> | Martin Zenker<sup>8</sup>

<sup>1</sup>Department of Orthodontics, University Hospital of Würzburg, Würzburg, Germany

<sup>2</sup>KOÇ University School of Medicine (KUSoM) Medical Genetics Department, Topkapi Zeytinburnu, Istanbul, Turkey

<sup>3</sup>Department of Clinical Genetics Medical University, Białystok, Poland

<sup>4</sup>Department of Physiology, Faculty of Medicine, University of Kelaniya, Ragama, Sri Lanka

<sup>5</sup>Orthodontic Unit, Lady Ridgway Hospital, Colombo, Sri Lanka

<sup>6</sup>Department of Pedodontics, Faculty of Dentistry, Istanbul University, Istanbul, Turkey

<sup>7</sup>Department of Maxillofacial and Plastic Surgery Medical University of Białystok, Poland

<sup>8</sup>Institute of Human Genetics, University Hospital, Magdeburg, Germany

<sup>9</sup>Institut de Génétique et de Biologie Moléculaire et Cellulaire (IGBMC), INSERM U1258, CNRS-UMR7104, Université de Strasbourg, Illkirch-Graffenstaden, France

<sup>10</sup>Hôpitaux Universitaires de Strasbourg (HUS), Pôle de Médecine et Chirurgie Bucco-Dentaires, Hôpital Civil, Centre de référence des maladies rares orales et dentaires, O-Rares, Filière Santé Maladies rares TETE COU, European Reference Network ERN CRANIO, Strasbourg, France

<sup>11</sup>Faculté de Chirurgie Dentaire, Université de Strasbourg, Strasbourg, France

**Correspondence**

Martin Zenker, Institute of Human Genetics,  
University Hospital Magdeburg,  
Leipziger Str. 44, 39120 Magdeburg, Germany.  
Email: martin.zenker@med.ovgu.de

**Funding information**

EU (ERDF) grant INTERREG V "RARENET",  
Grant/Award Number: 1.7

**Abstract**

Fraser syndrome (FS) is a rare autosomal recessive multiple congenital malformation syndrome characterized by cryptophthalmos, cutaneous syndactyly, renal agenesis, ambiguous genitalia, and laryngotracheal anomalies. It is caused by biallelic mutations of *FRAS1*, *FREM2*, and *GRIP1* genes, encoding components of a protein complex that mediates embryonic epithelial–mesenchymal interactions. Anecdotal reports have described abnormal orodental findings in FS, but no study has as yet addressed the orodental findings of FS systematically. We reviewed dental radiographs of 10 unrelated patients with FS of different genetic etiologies. Dental anomalies were present in all patients with FS and included hypodontia, dental crowding, medial diastema, and retained teeth. A very consistent pattern of shortened dental roots of most permanent teeth as well as altered length/width ratio with shortened dental crowns of upper incisors was also identified. These findings suggest that the *FRAS1*–*FREM* complex mediates critical mesenchymal–epithelial interactions during dental crown and root development. The orodental findings of FS reported herein represent a previously underestimated manifestation of the disorder with significant impact on orodental health for affected individuals.

This is an open access article under the terms of the Creative Commons Attribution License, which permits use, distribution and reproduction in any medium, provided the original work is properly cited.

© 2020 The Authors. *American Journal of Medical Genetics Part A* published by Wiley Periodicals, Inc.

Integration of dentists and orthodontists into the multidisciplinary team for management of FS is therefore recommended.

#### KEYWORDS

dental roots, Fraser syndrome, hypodontia, orodental health, taurodontism

## 1 | INTRODUCTION

Fraser syndrome (FS; OMIM PS219000) is a rare autosomal recessive multiple congenital malformation syndrome characterized by cryptophthalmos, cutaneous syndactyly, renal agenesis, ambiguous genitalia, and laryngotracheal anomalies. Several other developmental defects may also occur. The disorder is caused by biallelic mutations in either of the genes *FRAS1*, *FREM2*, and *GRIP1*, encoding components of a protein complex involved in embryonic epithelial-mesenchymal interactions (Jadeja et al., 2005; Vogel et al., 2012; Vrontou et al., 2003). Genetic defects of *FREM1*, another component of this complex, are the cause of the clinically related BNAR and MOTA syndromes (OMIM 608980 and 248450), suggesting that FS, BNAR, and MOTA syndromes form a spectrum of clinically overlapping FRAS-FREM complex diseases (Alazami et al., 2009; Slavotinek et al., 2011).

In 2002, Slavotinek and Tiffit provided a comprehensive clinical review of 117 published patients diagnosed with cryptophthalmos or FS and refined the diagnostic criteria proposed by Thomas et al. (Slavotinek & Tiffit, 2002; Thomas et al., 1986). Along with four major criteria, several minor criteria were selected as the diagnostic features of FS. Cleft lip and palate malformation was the only orodental finding that was considered as one of the minor criteria. Diniz et al. reported oral and dental findings in a single case and stated that some of the observed features, such as dental crowding, malocclusion, and ogival palate, had also been reported in a few other cases previously (Diniz, Lima, Sacono, de Paula, & dos Santos-Pinto, 2007). Keene et al. reported a second case in the dental literature and noted hypodontia and short dental roots in a 15-year-old female with FS (Keene & Day, 2011). A few more anecdotal reports have replicated the observation of hypodontia and short dental roots (Gallotini et al., 2018; Hassona, Kharoub, & Scully, 2017; Kantaputra et al., 2001). In the most recent publication on this topic including another case report and a literature review, Gallotini et al. summarized oral findings in FS to include oral clefting, high arched palate, malocclusion, ankyloglossia, fusion of primary teeth, hypodontia, microdontia, short roots, retained teeth, and dental crowding. They concluded that the short root anomaly was particularly related to FS (Gallotini et al., 2018).

As the current knowledge on orofacial and dental features in FS relies only on a few case reports, the aim of the present investigation was to verify these previously described dental anomalies by analyzing the orthopantomographs and dental X-rays of 10 unrelated patients diagnosed with FS.

## 2 | MATERIALS AND METHODS

Individuals with a definite diagnosis of FS ascertained in different centers were included in this study. The inclusion criteria were minimum age of 8 years (old enough to evaluate permanent dentition) and the availability of dental radiographs. In all included individuals, the diagnosis of FS had been confirmed by diagnostic molecular genetic testing. All diagnostic and therapeutic measures including dental radiograph imaging were part of the routine clinical care, and patients or their legal guardians gave their consent for using these data for this systematic study. All dental radiographs were independently reviewed by A.S.-E./F.K. and A.B.-Z., who are specialists in developmental dental anomalies. Assessments were compared, and where discrepancies in the interpretation of dental radiological morphology occurred, a consensus was reached by discussion. For all patients, information about major malformations characterizing FS (ocular, limb, renal, genital) and molecular genetic test results were submitted by the attending physicians using a questionnaire.

## 3 | CLINICAL DESCRIPTIONS

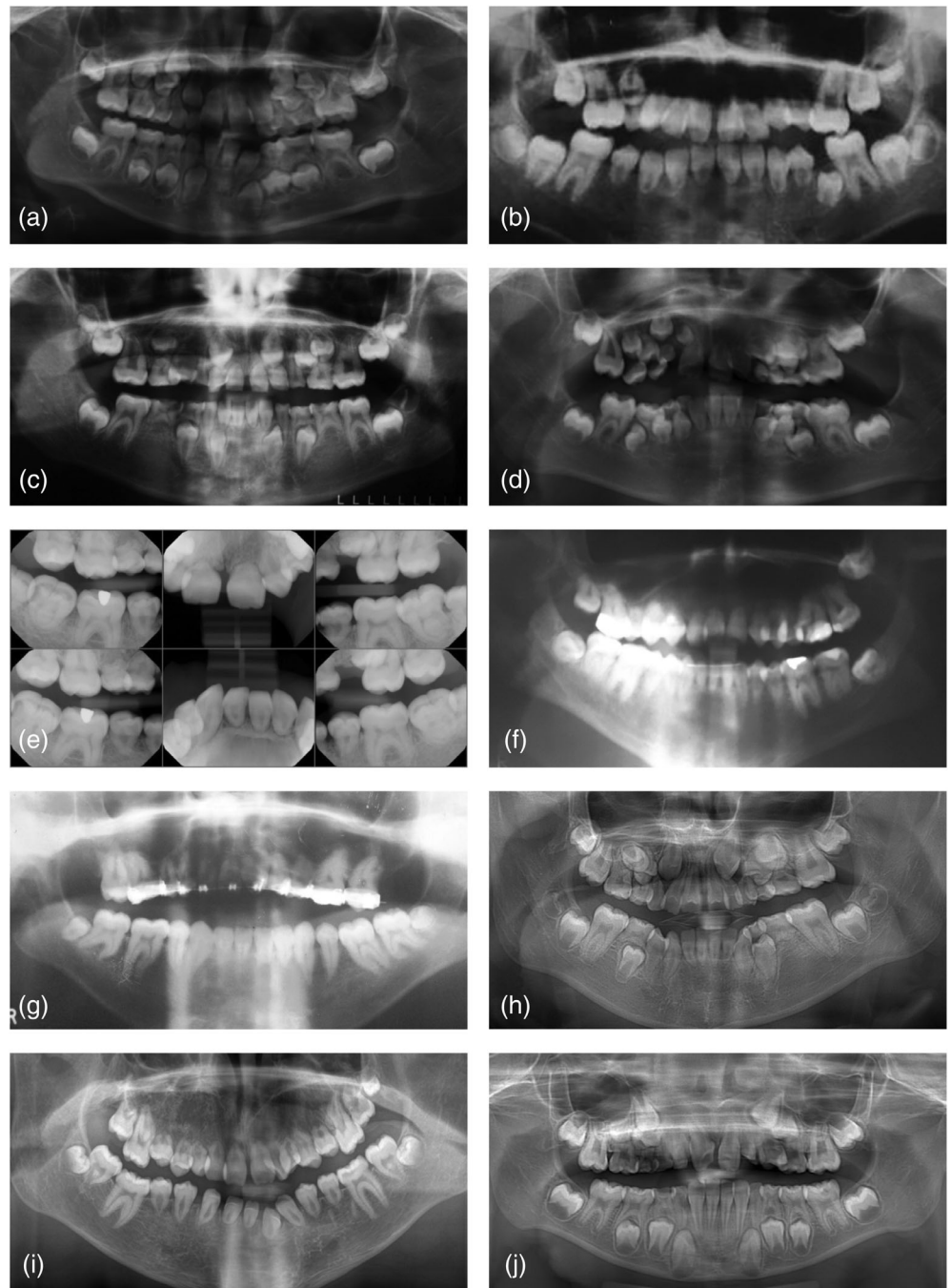
### 3.1 | Patient 1

This female patient was investigated at age 8 years 2 months. She had molecularly confirmed FS due to compound heterozygosity for the *FRAS1* mutations c.2163T>G (p.Cys721Trp) and c.11544del (p.Arg3849Aspfs\*8). Her major physical abnormalities included right cryptophthalmos, left upper eyelid coloboma, subglottic stenosis requiring tracheostomy, conductive deafness, syndactyly on both hands, right pelvic kidney, and genital anomalies. She presented to the Orthodontic Department especially because of hypoplasia of the maxilla with unilateral crossbite and increased overjet.

Radiological examination showed an age-appropriate dentition with the presence of 30 permanent teeth (Figure 1a). Due to crowding, the lateral upper incisors had not erupted. Agenesis of the lower right second permanent incisor (42) was noted and the tooth germ of the right upper third molar (18) was not visible (although the patient was too young to conclude agenesis for this third molar). All erupted incisors showed extremely short roots. In contrast, the first molars exhibited almost normal length of the roots and demonstrated taurodontism, especially in the upper jaw. There was also a space deficit for the germs of the canines and premolars especially in the upper jaw. In contrast, a diastema between the central incisors of the upper

**FIGURE 1** Dental x-ray images of the patients diagnosed with Fraser syndrome. (a–j) represent images from Patients 1–10, respectively.

Source: Figure 1b: Reprinted with permission from Midro et al., 2020, by John Wiley & Sons, Inc.



jaw was visible. The upper incisors showed an altered length/width ratio with shortened dental crowns.

### 3.2 | Patient 2

The female patient was 12 years at examination. She had molecularly confirmed FS due to homozygosity for the recurrent *FRAS1* mutation c.6963\_6964dup (p.Val2322Glyfs\*6). Her major congenital anomalies included right-sided cryptophthalmos, syndactyly of hands and feet, left kidney agenesis, laryngeal and choanal stenosis. Examination of stomathognathic system showed bilateral crossbite, increased overjet,

diastema between the upper incisors with a thick and palatally fixed labial frenulum, in addition to small crowns of teeth in the anterior and lateral segments. Her clinical and orodental findings have been reported recently (Midro et al., 2020).

The orthopantomograph showed the presence of 28 permanent teeth at a dental age of about 11 years (Figure 1b). One premolar on both sides in the upper jaw (15, 25) and one on the right side in the lower jaw (45) were missing. There was no tooth germ of the right upper third molar (18). Due to crowding, the premolar on the right side of the upper jaw and on the left side of the lower jaw had failed to erupt. All erupted permanent teeth exhibited very short roots with the exception of the first molars. All molars were taurodontic, and

the second molars seemed to be single rooted. A medial diastema between the upper incisors was present, and the upper incisors showed an altered length/width ratio with shortened dental crowns.

### 3.3 | Patient 3

The female patient was 10 years old at examination. She was found to be compound heterozygous for *FRAS1* mutations c.3727C>T (p.Arg1243\*) and c.10829\_10830insGTA (p.Tyr3610\*). Her major congenital anomalies included choanal and laryngeal stenosis and right kidney agenesis. At clinical orodental examination, a narrow mouth fissure, microgenia, and malocclusion in association with a thick, broad tongue frenulum were noted.

The radiological dental age of the female patient was about 9 years (Figure 1c). The lower permanent canines (33, 43) had not erupted by that age, whereas the upper right first premolar had already erupted into the oral cavity. The orthopantomograph showed the presence of 30 permanent teeth. There was agenesis of both second premolars in the lower jaw (35, 45). Except of the first molars, all erupted teeth exhibited very short roots. The first upper molars demonstrated pronounced taurodontism. The upper canines were displaced in the alveolar bone at the region of the lateral incisors maybe due to persistence of the deciduous canines. In addition, the germs of the lower permanent canines showed medial dystopia, and the deciduous canines in the lower jaw were still in occlusion. There was crowding for the upper canines and the upper left first premolar. A diastema between the upper central incisors was present, and all the upper incisors showed an altered length/width ratio with shortened dental crowns.

### 3.4 | Patient 4

The female patient was examined at age 8 years and 8 months. She was assumed to have *FRAS1*-related FS based on heterozygosity for the *FRAS1* nonsense mutations c.370C>T (p.Arg124\*), but the disease-causing variant on the second allele was not identified. She had congenital right symblepharon, syndactyly of first and second digits on both hands, agenesis of the left and hypoplasia of the right kidney in addition to ambiguous genitalia. Orthodontic treatment was started at the age of 8 years. All deciduous teeth were removed to facilitate spontaneous eruption of the permanent teeth, and a bone-borne palatal distractor was inserted to broaden the maxilla. Afterward, she wore a removable appliance.

The female patient showed an age-appropriate dentition (Figure 1d). Twenty-eight permanent teeth were visible on the orthopantomograph. No tooth germs of the third molars could be detected which is normal at that age. There was suspicion of agenesis of the right upper lateral incisor: the peg-shaped crown of the highly displaced, underdeveloped tooth in the area of the lateral upper incisor could represent a laterally displaced mesiodens or a small lateral incisor. The dental roots of all erupted permanent teeth except of the first

molars were extremely short, and the first upper molars were taurodontic. There was a space deficit for the upper and lower canines and premolars. A diastema between the upper central incisors was present. The upper incisors showed an altered length/width ratio with shortened dental crowns.

### 3.5 | Patient 5

The adult female patient has molecularly confirmed FS due to compound heterozygosity for a *FRAS1* nonsense mutation, c.2010T>A (p.Cys670\*) and a single exon deletion of Exon 5. Major clinical findings included right eyelid coloboma and symblepharon, cutaneous syndactyly affecting both hands, left kidney agenesis and right pelvic kidney, congenital hydrometrocolpos, and laryngeal stenosis. A labial frenulum was removed in childhood. She had a first orthodontic examination at age 11 years when significant dysgnathism and crowding of teeth were diagnosed. She wore fixed braces from age 12–13 years.

This patient had several periapical dental films available for review (Figure 1e). In the lower jaw, the third molars had already erupted into the oral cavity. According to the x-rays, agenesis of the right upper second premolar (15), both upper lateral incisors (12, 22), and one lower incisor can be assumed. There was failure of eruption of the upper left second premolar due to crowding. Except for the first molars, all other permanent teeth showed very short dental roots. A diastema between the upper central incisors was present, and a bony midline suture defect was additionally visible at this region. The upper incisors showed an altered length/width ratio with shortened dental crowns.

### 3.6 | Patient 6

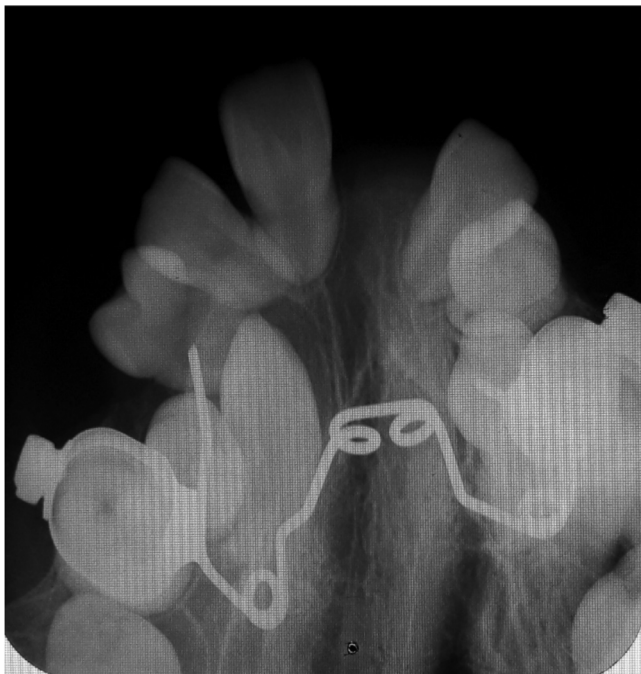The male patient (age 34 years) has molecularly confirmed FS caused by mutated *FRAS1*. He was found to have two heterozygous pathogenic variants in this gene: c.6551del (p.Leu2184\*) and c.10261C>T (p.Arg3421\*). He had left-sided cryptophthalmos, syndactyly affecting both hands and feet, laryngeal stenosis, and left kidney agenesis. Orthodontic treatment included a fixed appliance for the alignment of the dental arches. As the lower incisors became loose, they were retained with a bonded wire afterward.

His orthopantomograph showed the presence of 29 permanent teeth (Figure 1f). The upper right second molar (17), the upper left lateral incisor (22), and one lower incisor were absent. The presence of multiple restorations of the dental crowns led us to the presumption that the upper right second molar was missing due to extraction while the upper left lateral (22) and one lower incisors were missing due to agenesis. The upper left third molar (28) was displaced horizontally. Except for the first molars with almost normal length of the roots, all teeth showed very short dental roots. There was dental crowding for the right upper second premolar. A diastema between the upper central incisors was present. The upper incisors showed an altered length/width ratio with shortened dental crowns.

### 3.7 | Patient 7

This male adult had molecularly confirmed FS due to homozygosity for the *FREM2* pathogenic variant c.3495del (p.Arg1166Valfs\*17). He had congenital right-sided cryptophthalmos and cutaneous syndactyly of both hands and the right foot. His medical history included repair of cleft palate and surgical correction for right pelvi-ureteric junction obstruction and hypospadias. He first presented for orthodontic treatment at 11 years. Clinical evaluation identified a flat facial profile with mandibular deviation to the left, high arched palate with lateral crossbite and several missing teeth. The orthodontic treatment included rapid maxillary expansion applied at age 11 and 15 years. There was agenesis of the second premolars in the lower jaw, which leads to good alignment of the lower arch without any orthodontic treatment in the lower jaw. One upper central incisor was congenitally missing (21), and after the orthodontic alignment of the upper arch, the upper left lateral incisor (22) became mobile due to its very short root and was extracted because its prognosis was considered poor.

The orthopantomograph at the age of 19 years (Figure 1g) showed a fixed orthodontic appliance in the upper jaw. The left upper canine was aligned into the dental arch by orthodontic therapy. The additional occlusal x-ray of the maxilla (Figure 2), which was performed about a year before the orthopantomograph, showed palatal impaction of the upper right canine and severe crowding in the lateral segments, and this impacted canine was surgically removed in the time frame between the two x-rays. The upper third molars were missing, and the lower third molars were microdonts. In total, the patient showed 25 permanent teeth at that time. All incisors demonstrated extremely shortened roots. The roots of the upper canines and premolars were also moderately shortened. The canines and



**FIGURE 2** Occlusal x-ray of the upper jaw of Patient 7

premolars in the lower jaw exhibited pipette shaped roots, whereas the molars demonstrated blunted roots. The upper incisors showed an altered length/width ratio with shortened dental crowns.

### 3.8 | Patient 8

This female patient aged 9 years 7 months had molecularly confirmed FS due to homozygosity for the *FRAS1* mutation c. 4129+1G>A. Her major congenital anomalies included syndactyly of hands and feet, right-sided kidney agenesis, and ambiguous genitalia. She had no cryptophthalmos but the characteristic frontal hair pattern and other typical facial signs of FS. She had not received any orthodontic treatment before.

The radiological dental age of this female patient was about 10 years. The orthopantomograph (Figure 1h) showed the presence of 29 permanent teeth. No germs of the third molars in the upper jaw were present. There was agenesis of the left second premolar in the lower jaw (35). The roots of all canines and premolars, as well as the lower incisors were very short, and the roots of the upper incisors were slightly shortened as well. However, the first molars demonstrated almost normal length of the roots. Taurodontism was visible for the upper first molars. A very atypical order of the maturation of the dental roots was noted: the maturation of the roots of the first molars in the upper jaw was not completed, but the apices of all canines and the first lower premolars were almost closed. Due to severe space deficit in the upper jaw, there is a high risk of retention for the germs of the canines and premolars. There was a medial diastema in the upper jaw. The upper incisors showed an altered length/width ratio with shortened dental crowns and a hyperdeveloped palatal cingulum.

### 3.9 | Patient 9

The male patient was 13 years old and had molecularly confirmed FS due to compound heterozygosity for *FREM2* mutations c.2695C>T (p.Arg899\*) and c.5173+1G>T. The child had left cryptophthalmos, cutaneous syndactyly on both hands, left kidney agenesis, hypospadias, and laryngomalacia. He had not had any orthodontic treatment by that age.

The orthopantomograph showed a permanent dentition with the presence of 30 permanent teeth (Figure 1i). There was agenesis of the right third molar in the upper jaw (18) and of one incisor in the lower jaw. All teeth had extremely shortened roots with exception of all first molars exhibiting almost normal length of the roots; however, also the roots of these teeth had an abnormal morphology. This patient demonstrated very small maxillary sinus, large amount of spongy bone at the maxilla, and a broadened bony midline suture. The left lower lateral incisor showed failure of complete eruption, although there was no space deficit in this region. There was dental crowding in the upper jaw, especially in the area of the left lateral incisor and of the left canine. Nevertheless, this patient had a medial diastema in the upper

jaw. The upper incisors showed an altered length/width ratio with shortened dental crowns.

### 3.10 | Patient 10

The female patient was 8 years and 9 months old and had molecularly confirmed FS due to compound heterozygosity for a nonsense mutation c.2120C>A (p.Ser707\*) and an intragenic deletion encompassing exons 17 and 18 of the *GRIP1* gene. She had congenital bilateral palpebral defects with micro-syblepharon on the left and upper eyelid coloboma on the right, cutaneous syndactyly of both hands, right-sided renal agenesis and left-sided grade II hydronephrosis, a laryngeal web, and genital anomalies. The case has been reported along with molecular data in 2013 (Schanze et al., 2013).

The radiological dental age of this patient was about 8 years. The orthopantomograph (Figure 1j) showed a mixed dentition with the presence of 26 permanent teeth. There was agenesis of the left lateral incisor in the upper jaw (22) and the presence of the right lateral incisor in the upper jaw (12) could not be verified. No germs of the third molars could be detected. The first upper premolar on the left showed accelerated eruption, likely due to an early loss of the infected deciduous predecessor. Due to severe space deficit in the upper jaw, there is a high risk of retention for the tooth germs of the canines and premolars. The central upper incisors had shortened roots, while the roots of the lower incisors, as well as the roots of all first molars demonstrated almost normal length of the roots. Despite the almost normal length of the roots of the upper first molars, these teeth showed taurodontism with an apical shift of the trifurcation. This patient also had a medial diastema in the upper jaw.

## 4 | DISCUSSION

The aim of the present investigation was to systematically record and classify dental anomalies in patients with FS. We collected data from 10 unrelated FS individuals and focused our analysis on dental X-rays. There have been previous anecdotal reports on oral and dental anomalies in FS, which stimulated this study (de Oliveira & de Sant'Anna, 2014; Diniz et al., 2007; Gallottini et al., 2018; Hassona et al., 2017; Kantaputra et al., 2001; Keene & Day, 2011). We aimed to identify the frequency of dental anomalies in FS and verify their specific patterns.

Ten patients included in this study shared a number of dental abnormalities (Table 1). The most common dental anomalies we observed have already been noted in previous case reports (de Oliveira & de Sant'Anna, 2014; Diniz et al., 2007; Gallottini et al., 2018; Hassona et al., 2017; Ide & Wollschlaeger, 1969). All patients with FS studied here demonstrated agenesis of one or more permanent teeth (we are uncertain whether Patient 4 who has a tooth germ in the area of the lateral upper incisor has a displaced mesiodens or a small lateral incisor). Secondly, all patients presented with dental crowding at least in one region of the dental arch. In most cases, this space deficit was in the lateral areas of the upper jaw. As a

consequence of dental crowding, all patients displayed retention or delayed eruption of one or more permanent teeth. Thirdly, we found a medial diastema in the upper jaw in all patients except one (Patient 7) who had agenesis of an upper central incisor and already received orthodontic treatment before dental radiograph was obtained (dental x-rays before the onset of treatment were not available), although all patients demonstrated concomitant dental crowding. The reason for diastema is not likely to be a general excess of space. Possible explanations might be a thick and palatally fixed labial frenulum or an altered structure of the alveolar bone in this area. Fourthly, a recurrently reported dental feature in FS is shortened dental roots (Gallottini et al., 2018; Hassona et al., 2017; Keene & Day, 2011), which we confirmed as a consistent anomaly in this cohort. We observed dramatic shortening of dental roots in all patients. In the majority of cases, many teeth were affected, while in Patients 7 and 10, significant shortening of dental roots was observed only of the incisors. In contrast to the previous reports, none of our patients had shortened roots of the first molars; however, many of these molars were taurodonts. One previous case report suggested that FS might be associated with general microdontia (Hassona et al., 2017). In our cohort, none of the patients demonstrated general microdontia, but altered length/width ratio with shortened dental crowns of all upper incisors was present in all patients except Patient 10. In summary, this study does not only demonstrate that dental anomalies of permanent teeth are a frequent, if not consistent, finding in FS, our findings but further suggest that a very similar pattern of anomalies including hypodontia, dental crowding, and in particular the underdevelopment of dental roots can be considered as characteristic signs. The presented data are in apparent contrast to the paucity of previous reports on oral and dental anomalies in FS and to the fact that dental anomalies have not been mentioned in large reviews (Slavotinek & Tifft, 2002; Thomas et al., 1986). A major cause for underestimation/underdiagnosis may be related to high perinatal mortality of FS and the strong underrepresentation of adolescent or adult patients in the literature. As we selected subjects for this study by calling for dental radiographs from individuals with FS, we cannot exclude bias leading to an overestimation of dental anomalies, since individuals with no abnormal orodontal findings may be less likely to have a dental radiographic examination.

As all the patients had molecular diagnosis, we are able to state that the described dental findings are not confined to a distinct genetic etiology but are similarly present in patients with *FRAS1*, *FREM2*, and *GRIP1* mutations. This is consistent with the overall FS phenotype in which no significant differences have been established between individuals with *FRAS1*, *FREM2*, and *GRIP1* gene mutations. This also underscores the assumption that the integrity of the entire complex of FS-related proteins is required for normal tooth development. However, taking into account the genetic heterogeneity of FS and the limited number of patients studied here, we cannot fully exclude any genotype phenotype correlations regarding dental involvement in FS. Moreover, we have not been able to include patients with BNAR/MOTA syndrome to confirm that similar dental defects are also associated with deficiency of *FREM1*.

**TABLE 1** Radiological dental characteristics observed in individuals with Fraser syndrome

Patient	Gender	Age	Hypodontia (except third molars)	Radiological dental characteristics					
				Short roots	Taurodontism	Retained teeth/risk of retention	Dental crowding	Medial diastema	Altered length/width ratio of upper incisors crowns
1	F	8 years 2 months	Yes (one lower incisor)	Yes (except the first molars)	Yes	Yes	Yes	Yes	Yes
2	F	12 years	Yes (two upper premolars, one lower premolar)	Yes (except the first molars)	Yes	Yes	Yes	Yes	Yes
3	F	10 years	Yes (two lower premolars)	Yes (except the first molars)	Yes	Yes	Yes	Yes	Yes
4	F	8 years 8 months	Not sure (one upper lateral incisor)	Yes (except the first molars)	Yes	Yes	Yes	Yes	Yes
5	F	24 years	Yes (one upper premolar, both upper lateral incisors, one lower incisor)	Yes (except the first molars)	No	Yes	Yes	Yes	Yes
6	M	34 years	Yes (one upper lateral incisor, one lower incisor)	Yes (except the first molars)	No	Yes	Yes	Yes	Yes
7	M	19 years	Yes (one upper central incisor, two lower premolars)	Yes (incisors, upper canines and upper premolars)	No	Yes	Yes	?	Yes
8	F	9 years 7 months	Yes (one lower premolar)	Yes (except the first molars)	Yes	Yes	Yes	Yes	Yes
9	M	13 years	Yes (one lower incisor)	Yes (except the first molars)	No	Yes	Yes	Yes	Yes
10	F	8 years 9 months	Yes (one upper lateral incisor)	Yes (upper central incisors)	Yes	Yes	Yes	Yes	No

The FRAS1-FREM complex is an extracellular matrix complex that is expressed temporarily during the embryonic period at basal laminae and is believed to mediate adhesion as well as differentiation signals involving epithelial-mesenchymal interactions (Short, Wiradjaja, & Smyth, 2007). GRIP1 serves as a cytosolic adapter protein that is required for the transport of FRAS1 and FREM2 proteins to the surface of the epithelial cells. Several of the congenital defects that occur in FS (e.g., cryptophthalmos, syndactyly) are believed to represent the remnants of embryonic blistering that has been clearly demonstrated in mouse and zebrafish models of FS (Smyth & Scambler, 2005). Other common defects (e.g., renal agenesis, genital anomalies) are probably related to disturbed epithelial-mesenchymal interactions during organ development. The functions of FS-related proteins have been extensively studied in kidney morphogenesis where the crosstalk between epithelial cells of the ureteric bud and the metanephric mesenchyme is known to play a critical role. The current knowledge suggests that the FRAS1-FREM complex serves as a scaffold for the assembly of nephronectin at the ureteric bud basement membrane. Nephronectin acts as a ligand for integrin  $\alpha 8 \beta 1$ , expressed by metanephric mesenchymal cells, thereby inducing GDNF

signaling (Kiyozumi et al., 2012). Without the FS-related complex, nephronectin becomes degraded and the interaction between nephronectin and integrin  $\alpha 8 \beta 1$  is significantly weakened. During tooth development, very similar processes may play a role. Notably, nephronectin, the protein whose stabilization at basement membranes is dependent on the interaction with FS-related proteins is known to be a key regulator also for dental development and dental stem cell fate (Arai et al., 2017; Tang & Saito, 2017). Consistently, FS-related genes (*Fras1*, *Frem1*, *Frem2*) are strongly expressed at E14.5 in the developing teeth in mice (Laugel-Haushalter et al., 2013). Moreover, evidence suggests that epithelial-mesenchymal interactions are involved in dental root development (Chen et al., 2014; Itaya et al., 2017). Therefore, we hypothesize that the defect of FS-related proteins may lead to the distinct pattern of dental anomalies described here, by the disruption of nephronectin-mediated epithelial-mesenchymal interactions in developing teeth. Further functional assays are needed to verify molecular mechanisms underlying FS-associated dental defects.

The observed dental anomalies are not just a previously underdiagnosed sign of FS. They do in fact have significant impact on oral and dental health of affected individuals. Hypodontia and dental

crowding is associated with malocclusion and shortened dental roots lead to an increased risk of early tooth loss, which strongly limit opportunities for orthodontic therapy. It is doubtful whether mobilization and alignment of retained teeth or the orthodontic alignment of the other teeth besides the first molars are possible in patients with FS because of the increased risk to other teeth, especially their roots. Prosthetic management options are also limited in patients with FS. We concur with Gallottini et al. that the early detection of short roots and hypodontia enables better planning for successful dental rehabilitation during the permanent dentition phase (Gallottini et al., 2018).

## 5 | CONCLUSION

This study establishes distinct dental anomalies as a very frequent finding in patients with FS. The abnormalities comprise of hypodontia, dental crowding, medial diastema, retained teeth, and a very consistent pattern of shortened dental roots in almost all permanent teeth as well as altered length/width ratio with shortened dental crowns of upper incisors. These findings suggest that the FRAS1–FREM complex mediates critical mesenchymal–epithelial interactions during dental (root) development. The observed anomalies have a significant impact on orodental health for individuals affected by FS and make the orthodontic management very challenging. Multidisciplinary management in reference centers for rare oral and dental diseases is recommended.

## ACKNOWLEDGMENTS

We are indebted to all patients who participated in this research and made it possible. This work was supported by EU (ERDF) grant INTERREG V “RARENET” number 1.7 to A.B.Z.

## CONFLICT OF INTEREST

The authors declare no conflict of interest.

## AUTHOR CONTRIBUTIONS

M.Z., F.K., and A.S.-E. designed the study. H.K., F.K., A.M., D.d.S., S.B., Y.G., and J.B. were involved in acquisition, analysis and interpretation of data from affected individuals and provided clinical summaries. F.K., A.S.-E., and A.B.-Z. reviewed and rated all dental radiographs. D.S. and M.Z. generated and analyzed molecular genetic data. F.K., A.B.-Z., and M.Z. drafted and revised the manuscript.

## DATA AVAILABILITY STATEMENT

Data sharing is not applicable to this article as no new data were created or analyzed in this study.

## ORCID

Hülya Kayserili  <https://orcid.org/0000-0003-0376-499X>

Alina Midro  <https://orcid.org/0000-0002-9889-1969>

Agnes Bloch-Zupan  <https://orcid.org/0000-0002-6511-2615>

Martin Zenker  <https://orcid.org/0000-0003-1618-9269>

## REFERENCES

- Alazami, A. M., Shaheen, R., Alzahrani, F., Snape, K., Saggar, A., Brinkmann, B., ... Alkuraya, F. S. (2009). FREM1 mutations cause bifid nose, renal agenesis, and anorectal malformations syndrome. *American Journal of Human Genetics*, 85(3), 414–418. <https://doi.org/10.1016/j.ajhg.2009.08.010>
- Arai, C., Yoshizaki, K., Miyazaki, K., Saito, K., Yamada, A., Han, X., ... Fukumoto, S. (2017). Nephronectin plays critical roles in Sox2 expression and proliferation in dental epithelial stem cells via EGF-like repeat domains. *Scientific Reports*, 7, 45181. <https://doi.org/10.1038/srep45181>
- Chen, J., Chen, G., Yan, Z., Guo, Y., Yu, M., Feng, L., ... Tian, W. (2014). TGF-beta1 and FGF2 stimulate the epithelial-mesenchymal transition of HERS cells through a MEK-dependent mechanism. *Journal of Cellular Physiology*, 229(11), 1647–1659. <https://doi.org/10.1002/jcp.24610>
- de Oliveira, T. L., & de Sant'Anna, G. R. (2014). Fraser syndrome-oral manifestations and a dental care protocol. *Case Reports in Dentistry*, 2014, 486108. <https://doi.org/10.1155/2014/486108> 5 pages.
- Diniz, M. B., Lima, L. M., Sacono, N. T., de Paula, A. B., & dos Santos-Pinto, L. (2007). Clinical manifestations and oral findings in Fraser syndrome. *Journal of Dentistry for Children (Chicago, Ill.)*, 74(3), 231–235.
- Gallottini, M., Llanos, A. H., Romito, G. A., Romano, M. M., de Oliveira, F. B., & de Rezende, N. P. M. (2018). Oral manifestations and rehabilitation in Fraser syndrome: A case report. *Special Care in Dentistry*, 38(4), 249–254. <https://doi.org/10.1111/scd.12297>
- Hassona, Y., Kharoub, H., & Scully, C. (2017). Oral healthcare in Fraser syndrome. *Special Care in Dentistry*, 37(5), 263–266. <https://doi.org/10.1111/scd.12247>
- Ide, C. H., & Wollschlaeger, P. B. (1969). Multiple congenital abnormalities associated with cryptophthalmia. *Archives of Ophthalmology*, 81(5), 638–644.
- Itaya, S., Oka, K., Ogata, K., Tamura, S., Kira-Tatsuoka, M., Fujiwara, N., ... Harada, H. (2017). Hertwig's epithelial root sheath cells contribute to formation of periodontal ligament through epithelial-mesenchymal transition by TGF-beta. *Biomedical Research*, 38(1), 61–69. <https://doi.org/10.2220/biomedres.38.61>
- Jadeja, S., Smyth, I., Pitera, J. E., Taylor, M. S., van Haelst, M., Bentley, E., ... Scambler, P. J. (2005). Identification of a new gene mutated in Fraser syndrome and mouse myelencephalic blebs. *Nature Genetics*, 37(5), 520–525. <https://doi.org/10.1038/ng1549>
- Kantaputra, P., Eiumtrakul, P., Matin, T., Opastirakul, S., Visrutaratna, P., & Mevate, U. (2001). Cryptophthalmos, dental and oral abnormalities, and brachymesophalangy of second toes: New syndrome or Fraser syndrome? *American Journal of Medical Genetics*, 98(3), 263–268.
- Keene, E. J., & Day, P. F. (2011). Case report: Hypodontia and short roots in a child with Fraser syndrome. *European Archives of Paediatric Dentistry*, 12(4), 216–218.
- Kiyozumi, D., Takeichi, M., Nakano, I., Sato, Y., Fukuda, T., & Sekiguchi, K. (2012). Basement membrane assembly of the integrin alpha8beta1 ligand nephronectin requires Fraser syndrome-associated proteins. *The Journal of Cell Biology*, 197(5), 677–689. <https://doi.org/10.1083/jcb.201203065>
- Laugel-Haushalter, V., Paschaki, M., Thibault-Carpentier, C., Dembele, D., Dolle, P., & Bloch-Zupan, A. (2013). Molars and incisors: Show your microarray IDs. *BMC Research Notes*, 6, 113. <https://doi.org/10.1186/1756-0500-6-113>
- Midro, A. T., Stasiewicz-Jarocka, B., Borys, J., Hubert, E., Skotnicka, B., Hassmann-Poznanska, E., ... Zenker, M. (2020). Two unrelated families with variable expression of Fraser syndrome due to the same pathogenic variant in the FRAS1 gene. *American Journal of Medical Genetics. Part A*, 182, 773–779. <https://doi.org/10.1002/ajmg.a.61495>
- Schanze, D., Harakalova, M., Stevens, C. A., Brancati, F., Dallapiccola, B., Farndon, P., ... Zenker, M. (2013). Ablepharon macrostomia syndrome: A distinct genetic entity clinically related to the group of FRAS-FREM



- complex disorders. *American Journal of Medical Genetics. Part A*, 161A (12), 3012–3017. <https://doi.org/10.1002/ajmg.a.36119>
- Short, K., Wiradjaja, F., & Smyth, I. (2007). Let's stick together: The role of the Fras1 and Frem proteins in epidermal adhesion. *IUBMB Life*, 59(7), 427–435. <https://doi.org/10.1080/15216540701510581>
- Slavotinek, A. M., Baranzini, S. E., Schanze, D., Labelle-Dumais, C., Short, K. M., Chao, R., ... Zenker, M. (2011). Manitoba-oculo-trichonal (MOTA) syndrome is caused by mutations in FREM1. *Journal of Medical Genetics*, 48(6), 375–382. <https://doi.org/10.1136/jmg.2011.089631>
- Slavotinek, A. M., & Tiffit, C. J. (2002). Fraser syndrome and cryptophthalmos: Review of the diagnostic criteria and evidence for phenotypic modules in complex malformation syndromes. *Journal of Medical Genetics*, 39(9), 623–633.
- Smyth, I., & Scambler, P. (2005). The genetics of Fraser syndrome and the blebs mouse mutants. *Human Molecular Genetics*, 14(suppl\_2), R269–R274. <https://doi.org/10.1093/hmg/ddi262>
- Tang, J., & Saito, T. (2017). The role of Nephronectin on proliferation and differentiation in human dental pulp stem cells. *Stem Cells International*, 2017, 2546261–2546214. <https://doi.org/10.1155/2017/2546261>
- Thomas, I. T., Frias, J. L., Felix, V., Sanchez de Leon, L., Hernandez, R. A., & Jones, M. C. (1986). Isolated and syndromic cryptophthalmos. *American Journal of Medical Genetics*, 25(1), 85–98. <https://doi.org/10.1002/ajmg.1320250111>
- Vogel, M. J., van Zon, P., Brueton, L., Gijzen, M., van Tuil, M. C., Cox, P., ... van Haelst, M. M. (2012). Mutations in GRIP1 cause Fraser syndrome. *Journal of Medical Genetics*, 49(5), 303–306. <https://doi.org/10.1136/jmedgenet-2011-100590>
- Vrontou, S., Petrou, P., Meyer, B. I., Galanopoulos, V. K., Imai, K., Yanagi, M., ... Chalepakis, G. (2003). Fras1 deficiency results in cryptophthalmos, renal agenesis and blebbed phenotype in mice. *Nature Genetics*, 34(2), 209–214. <https://doi.org/10.1038/ng1168>

**How to cite this article:** Kunz F, Kayserili H, Midro A, et al. Characteristic dental pattern with hypodontia and short roots in Fraser syndrome. *Am J Med Genet Part A*. 2020;182A: 1681–1689. <https://doi.org/10.1002/ajmg.a.61610>