

A cadaveric study on superior hypogastric plexuses

V. Abey Suriya, H.G.L. Akalanka, S. Kumarage
Faculty of Medicine, University of Kelaniya, Sri Lanka

Keywords: Pelvis, Nerve plexus, Hypogastric nerve, Surgery, Cadaver

Abstract

Introduction

The superior hypogastric plexus (SHP) is found around the level of aortic bifurcation. It is important in surgical procedures in the pelvis.

Methods

Ten (5; M & 5; F) fresh intact adult human cadavers were dissected. Following the initial dissection, all of them were further sectioned sagittal in the midline and separated in to half pelvises, and assessed. The study was carried out in the Department of Anatomy, Faculty of medicine Ragama, Sri Lanka from 2022 to 2024. The ethical clearance was obtained.

Results

In all specimens, left connecting fibers from the inferior mesenteric plexuses (IMA) crossed the left common iliac artery and joining to the superior hypogastric plexuses. In 80%, right connecting nerve fibers from the inferior mesenteric plexuses crossed the right common iliac artery and joined the superior hypogastric plexus (SHP). Eighty percent of the specimens had, well-defined nerve strands, whereas 20% contained a delicate and irregular meshwork. In all of the specimens, the median root, or a nerve root from abdominal aortic plexus from the IMA were present. In 80% specimens, the SHP was located between the aortic bifurcation and the sacral promontory. In 20%, it extended across the pelvic brim and ended on the body of the S1 vertebra.

Conclusion

The majority of the SHP were located below the aortic bifurcation and had well-defined nerve strands, rest traversed the pelvic brim and terminated on the body of the S1 vertebra. Further larger sample studies are recommended.

Introduction

The superior hypogastric plexus (SHP) is a pre aortic nervous plexus which has two lateral roots and a median root at the level of the aortic bifurcation. Lateral nerve roots begin predominately from the lowest lumbar splanchnic nerves (LSNs) and they contain sympathetic nerves. The median root which begins from the abdominal aortic plexus and traverse to the inferior mesenteric plexus, carries both sympathetic and parasympathetic fibers. From the SHP ,hypogastric nerves begin at or below the sacral promontory.[1-2] Surgical procedures in the pelvis, such as rectal, prostatic and gynecological are known to be associated with postoperative complications such as urinary, defecating, and sexual disorders. Inadvertent autonomic denervation during the procedure is believed to cause these post operative complications [3-5]. The objective of this study was to describe the anatomy of the SHP.

Methods

Ten (5; males and 5; females) fresh intact adult human cadavers were dissected. Following the initial dissection, all of them were further sectioned sagittally in the midline and separated in to half pelvises, and assessed. The study was carried out in the department Anatomy, Faculty of medicine, Ragama, Sri Lanka from 2022 to 2024. The ethical clearance was obtained. No conflict of interest.

Dissection: Step 01: The removal of the anterior abdominal wall, the small bowel and mesentery and the proximal colon revealed the aorta and the origin of the IMA. Between superior and inferior mesenteric arteries, the pre aortic plexus was found following the removal of the peritoneum.


Dissection: Step 02: The peritoneum removed to expose the nerves from the abdominal aortic plexuses which course around the inferior mesenteric artery to form the inferior mesenteric plexus, continuing into the SHP just below the aortic bifurcation. Traction anteriorly on the rectum created the retro-rectal space.

Results

In all our specimens, left connecting nerves from the inferior

Correspondence: V. Abey Suriya

E-mail: vasithaabey@hotmail.com

 <https://orcid.org/0000-0002-0986-7917>

Received: 28-05-2024 Accepted: 12-07-2024

DOI: <http://doi.org/10.4038/sljs.v42i2.9152>



mesenteric plexuses (IMP) crossed the left common iliac artery joining to the superior hypogastric plexuses. In 2/10 cases (20%), right connecting nerve fibers from the inferior mesenteric plexuses traveled to the abdominal aorta and crossed its bifurcation joining the superior hypogastric plexuses. In 8/10 samples (80%), right connecting nerve fibers from the inferior mesenteric plexuses crossed the right common iliac artery and joined the SHP. 8/10 (80%) specimens had, well-defined strands, whereas 2/20 (20%) contained a delicate and irregular meshwork. There were no, single or dual nerves noted with relevance to the left and right connecting nerve fibers. In all of the specimens, the median root from the inferior mesenteric plexus were present. In 8/10 (80%) specimens, the superior hypogastric plexus located between the aortic bifurcation and the sacral promontory while slightly to the left of the midline. In 2/10 (20%), it crossed the pelvic brim and ended on the body of the S1 vertebral body. Its lower segment traversed laterally and formed a triangular structure. From its base left and right hypogastric nerves began. Then the nerves travelled inferolaterally along the rim of the lesser pelvis. (Figure: 1) In all of the specimens the lower segment of the SHP was found posterior to the sigmoid mesocolon.

Discussion

According to the available literature, the SHP is a retroperitoneal structure. It is formed below the origin of IMA and placed marginally left to the midline. At the level of the sacral promontory, in between the left and right common iliac arteries the SHP was lying anterior to the aortic bifurcation and the left common iliac vein [2, 5]. According to the literature, the most of the lower segment of the SHP was found behind to the mesocolon of the sigmoid while placed right to the superior rectal artery [5]. The literature suggest that the majority of SHPs terminates at the sacral promontory. However the data also suggest that in some it terminates at the level of the distal portion of the vertebral body of S1. [2, 6]. Different morphologies of the SHP have been described such as a plexiform morphology, two distinct nerves, a single nerve or a broadened band-like nerve trunk. [1-7].

Furthermore, the literature revealed that the SHP contains two lateral and a median root. The median root is the caudal extension of the pre aortic plexus which is made up of superior mesenteric (SMP), inter-mesenteric, and IMP plexuses [2]. The lateral roots of the SHP contains both sympathetic and parasympathetic fibers. The lumbar splanchnic nerves of L3-4 forms these sympathetic nerves. There is a contribution from the pelvic splanchnic nerves (PSNs) which carry parasympathetic nerves. These nerves (PSNs) travel cranially from the inferior hypogastric plexus (IHP) through both hypogastric nerves [5]. The median root of the SHP contains

both sympathetic and parasympathetic fibers as well [2-8].

Our study results are also in keeping with the available data. In our study in all samples, left connecting nerve from the IMPs crossed the left common iliac artery and joined to the superior hypogastric plexuses. In 20%, right connecting nerve fibers from the inferior mesenteric plexuses travelled up to the abdominal aorta and crossed its bifurcation joining the SHP. In 80%, right connecting nerve fibers from the inferior mesenteric plexuses crossed the right common iliac artery and joined the SHP. Majority of specimens had, well-defined strands, whereas 20% had delicate and irregular networks. There were no, single or dual nerves noted with relevance to the left and right connecting nerve fibers. In all of the specimens, the median root, or a continuation of the abdominal aortic plexus from the inferior mesenteric plexus were present. In 80% specimens, the SHP was located between the aortic bifurcation and the sacral promontory while slightly to the left of the midline. In 20%, it crossed the pelvic brim and terminated at the S1 vertebral body level. Its lower segment formed a triangular structure and from its base left and right hypogastric nerves originated. Then it travelled inferolaterally along the rim of the lesser pelvis. In all of the specimens the lower segment of the SHP is located behind the sigmoid mesocolon. (Figure: 1)

Our major limitation of this study was the small number of samples. The reason for this limitation was the scarcity of fresh cadavers and the necessity of meticulous labour intensive dissection. Therefore we do not extrapolate our

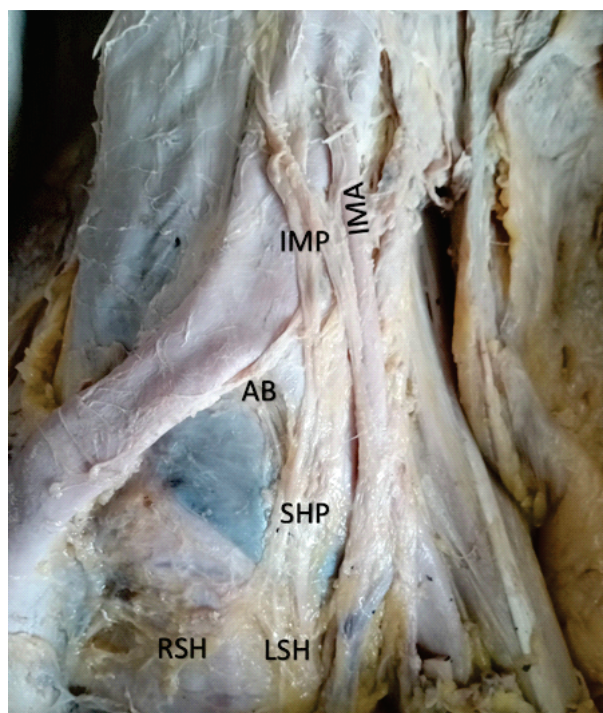


Figure 1. The superior hypogastric plexus

findings as the standard. This is a pilot study and Studies with a larger sample size and preferably intraoperative mapping will be of use to accurately map the anatomy of the SHP.

Conclusion

SHP was located below the aortic bifurcation in a majority and had well defined nerve strands that extended across the pelvic brim terminating at the level of the S1 vertebral body. The comprehensive knowledge on SHP with regard to its formation and location will avoid the iatrogenic injuries during surgical procedures in the pelvis. Further studies with larger samples are recommended.

References

1. Kraima AC, van Schaik J, Susan S, et al. New insights in the neuroanatomy of the human adult superior hypogastric plexus and hypogastric nerves. *Auton Neurosci*. 2015; 189: 60–67,
2. Beveridge TS, Fournier DE, Groh AMR, et al. The anatomy of the infrarenal lumbar splanchnic nerves in human cadavers: implications for retroperitoneal nerve-sparing surgery. *J Anat*. 2018; 232(1): 124–133.
3. Lu S, Xu Yq, Chang S, et al. Clinical anatomy study of autonomic nerve with respect to the anterior approach lumbar surgery. *Surg Radiol Anat*. 2009; 31(6): 425–430.
4. McCullough M, Valceus J, Downes K, et al. The ureter as a landmark for robotic sacrocolpopexy. *Female Pelvic Med Reconstr Surg*. 2012; 18(3): 162–164.
5. Paraskevas G, Tsitsopoulos P, Papaziogas B, et al. Variability in superior hypogastric plexus morphology and its clinical applications: a cadaveric study. *Surg Radiol Anat*. 2008; 30(6): 481–488.
6. Ripperda CM, Jackson LA, Phelan JN, et al. Anatomic relationships of the pelvic autonomic nervous system in female cadavers: clinical applications to pelvic surgery. *Am J Obstet Gynecol*. 2017; 216(4): 388.e1–388.e7.
7. Shi R, Wei W, Jiang P. Laparoscopic nerve-sparing radical hysterectomy for cervical carcinoma: emphasis on nerve content in removed cardinal ligaments. *Int J Gynecol Cancer*. 2016; 26(1): 192–198.
8. van Schaik J, van Baalen JM, Visser MJ, et al. Nerve-preserving aortoiliac reconstruction surgery: anatomical study and surgical approach. *J Vasc Surg*. 2001; 33(5): 983–989.