

# Solid pseudopapillary tumour of the pancreas: an uncommon pancreatic tumour in Sri Lanka

S.B. Tillakaratne, S.Cooray, B. Gunetilleke, R. Siriwardana  
Faculty of Medicine, University of Kelaniya, Sri Lanka

**Keywords:** Solid pseudopapillary tumour, Sri Lanka, Surgical resection

## Abstract

### Introduction and objectives

Solid pseudopapillary tumour of the pancreas (PST) is a rare exocrine pancreatic tumour commonly involving the body and the tail of the pancreas. It's seen predominantly in young women. Even patients who present with metastatic disease have good survival after resection. We looked at our experience with this rare tumour.

### Methods

Prospectively collected proforma-based data were analysed.

### Results

14 patients underwent surgery for PST from November 2011 to October 2022. 13 (93%) were females. The median age was 28 years (15-50). Nine (64.3%) patients presented with abdominal pain, and 3(21.4%) had an abdominal mass at presentation. Only 2(14.3%) patients were incidentally detected. The median tumour diameter was 7.2cm (2-18).7(50%) had involvement of the pancreatic body, 6(43%) had involvement of the head of the pancreas, and one had involvement of both the head and the body of the pancreas. Only one patient (7.14%) had liver metastasis at presentation. Distal pancreatectomy was performed in 6(43%), Whipple's pancreaticoduodenectomy in 6(43%), enucleation in 1(7.14%) and total pancreatectomy in 1(7.14%). In addition, liver metastasectomy was done in 1(7.14%) patient. There were no major complications. None received adjuvant treatment. At a median follow-up of 22 months, there were no recurrences.

### Conclusions

PST in our cohort were in young females who had excellent survival after surgical resection. Involvement of the head of

the pancreas was common compared to the predominantly distal disease in the available literature.

## Introduction

A solid pseudopapillary tumour (SPT) of the pancreas, also known as Frantz Tumour, is a rare exocrine pancreatic tumour. It amounts to 1-2% of pancreatic tumours (1). The pathogenesis of the tumour is unknown. It is commonly seen in young women presenting in the second or third decade of life. This preponderance suggests a link with sex hormones(2). The patients often present with features of mass effect, including abdominal pain or discomfort, nausea, and loss of appetite. Some are diagnosed incidentally on imaging. SPTs are of low malignant potential, with less than 15% of patients developing metastatic disease. Recurrences are as low as 10% commonly reported within the first four years after surgery(3). However, metastasis to the liver and regional lymph nodes and direct invasion to the duodenum, stomach, spleen or major blood vessels may be seen in a minority of patients(3).

Complete surgical resection of the tumour is the treatment of choice. Close to 95% of patients have the tumour limited to the pancreas, making radical resection possible (4). The 5-year survival rate of patients with solid pseudopapillary tumours is around 96%. The prognosis is considered good following resection, even in patients with metastatic disease. (5)


Being a rare neoplasm, the existing data on patient characteristics and survival of patients with solid pseudopapillary neoplasms in Sri Lanka is limited. Thus data from a Sri Lankan cohort would help us identify predictors of the disease and guide the management of the patients in the local settings.

## Methodology

This descriptive study was carried out as a retrospective data analysis of the SPT patient registry and database maintained by the Colombo North Centre for Liver Diseases (CNCLD). Patients with SPT referred to the clinic from November 2011 to October 2022 were included in the study. The database

Correspondence: S.B. Tillakaratne

E-mail: suchinthat@gmail.com

 <https://orcid.org/0000-0002-6499-4644>

Received: 26-11-2023 Accepted: 15-07-2024

DOI: <http://doi.org/10.4038/sljs.v42i2.9096>



contains data collected on admission and at each follow-up visit. Demographic data, the clinical presentation of the patient, findings on imaging, the management of the patient including the type of surgery, intra-operative details and post-op complications, the duration of hospital and Intensive care unit (ICU) stay, histology findings of the resected specimens and details of adjuvant therapy were collected in proformas. The findings during the follow-up visits were entered into the database.

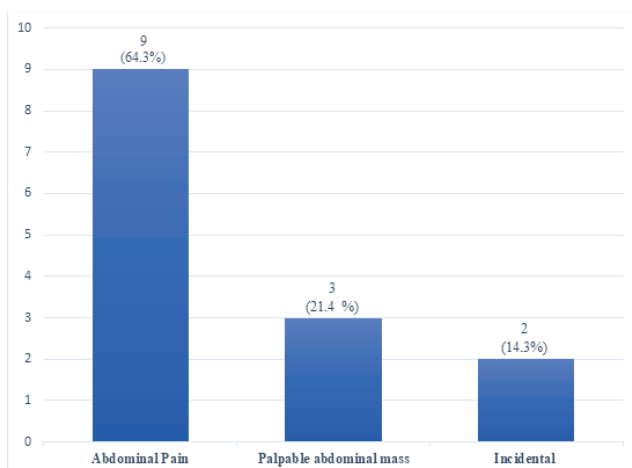
The data management and analysis were done using SPSS 26.0 software. The survival rates were calculated using the Kaplan mere survival curves. A p-value of <0.05 was taken as significant. The required ethical clearance was obtained from the Ethical Review Committee of the Faculty of Medicine, University of Kelaniya.

### Results

The study sample constituted 14 patients referred and managed at the Colombo North Centre for Liver Diseases from November 2011 to October 2022. The sample showed a female preponderance of 93% (n=13) with a median age of 28 (15-50).

Abdominal pain alone was the presenting complaint in a majority of 64.3% (n=9). A palpable abdominal mass was only found in 21.4% (n=3), and 14.3% (n=2) were diagnosed incidentally. USS showed a median tumour diameter of 5.5 cm (4-18), while the CT abdomen showed a median tumour diameter of 7.10 cm (3-18).

Six patients (42.8%) had tumours located on the right side of the portal vein with the involvement of the head or the



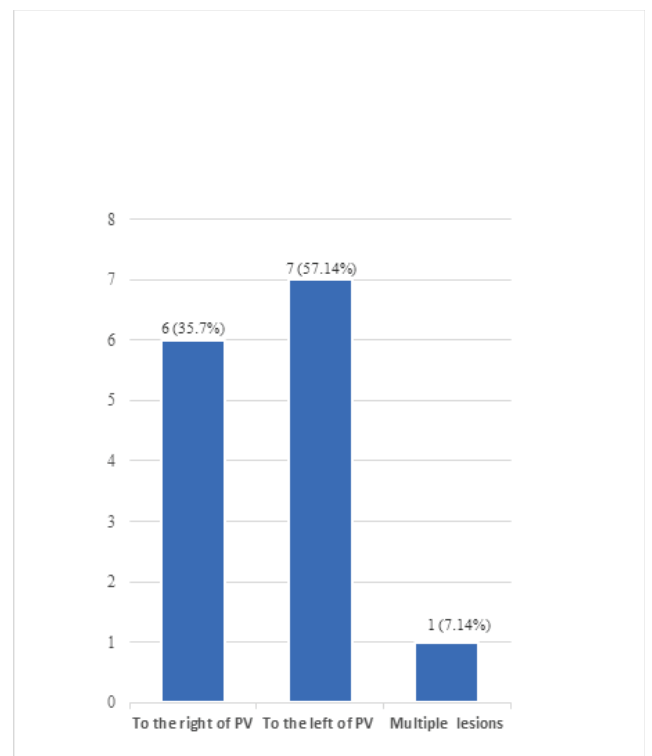
**Figure 1.** Symptoms at presentation

uncinate process of the pancreas. These patients underwent Whipple's pancreaticoduodenectomy. Seven patients (50%) had tumours on the left side of the portal vein in the body and the tail of the pancreas. They underwent distal pancreatectomy and splenectomy except for one patient with a small tumour which was enucleated. One patient (7.1%) underwent total pancreatectomy due to multiple tumours in the head, body and tail of the pancreas. One patient (7.1%) had liver metastasis at presentation, and liver metastasectomy was done along with distal pancreatectomy for the primary in the pancreatic tail.

The median hospital stay was 7.6 days, and the median ICU stay was 2.7 days. There were no major surgical complications. 1 (7.1%) developed an intra-abdominal infection which was treated successfully with antibiotics, while another 21.4% (n=3) had minor post-operative chest complications.

The histology of the resected specimens confirmed the diagnosis of SPT in all patients, with clear margins in 93% (n=13) and no lymphovascular invasion in any. The median diameter of the resected specimens was 8.5 cm (3.5-18.0)

None received adjuvant treatment. There were no recurrences at a median follow-up of 22(2-70) months.



**Figure 2.** Location of the tumour in the pancreas

## Discussion

Solid pseudopapillary tumours are commonly seen in the body or the tail of the pancreas(6). Therefore, the commonest surgical procedure performed in the literature is distal pancreatectomy with splenectomy. However, in this cohort, the tumour had equal distribution in the head and the body-tail regions, with almost equal number of Whipple's surgeries and distal pancreatectomies being performed.

The tumours in the body and the pancreas' tail were larger than those in the head and neck region.

There were relatively fewer post-operative complications compared to other major pancreatic resections. This could be because the patient population was young and otherwise healthy. The outcome after surgical resection was excellent, even with liver metastasectomy. All the patients are alive and recurrence free at a median follow-up of 22 months.

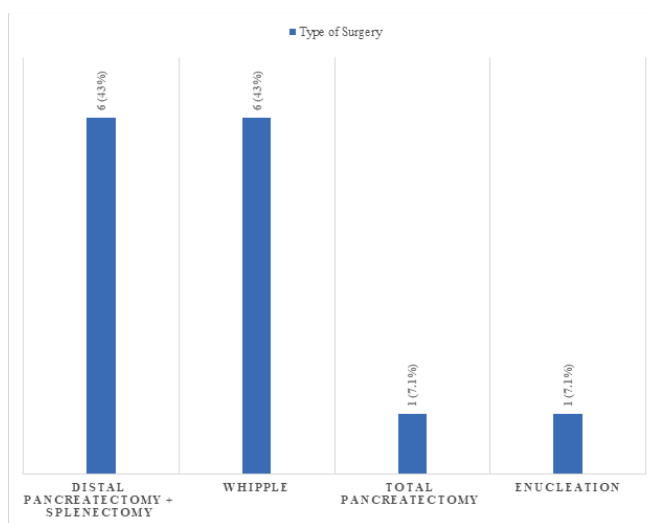
Most patients were symptomatic at the presentation, with only 14.5% asymptomatic. However, this pattern may change with the detection of asymptomatic patients with the increasing availability of abdominal ultrasound.

The follow-up after surgical resection for PST is questionable. There is the argument that due to the inherent benign nature of the tumour and the slow growth, there need not be any follow-up unless the patient presents with symptoms. However, there are case reports of aggressive and rapidly growing PST tumours, making it worthwhile to do interval imaging in the first few years after resection(7) with the possibility of re-resection.

In conclusion, the disease was seen among young females, and the outcomes were excellent after surgical resection. The disease in the head of the pancreas was equally common compared to the predominantly distal disease in the reported literature.

## References

1. Ng KH, Tan PH, Thng CH, Ooi LL. Solid pseudopapillary tumour of the pancreas. *ANZ J Surg.* 2003.
2. Antoniou EA, Damaskos C, Garmpis N, Salakos C, Margonis GA, Kontzoglou K, et al. Solid pseudopapillary tumor of the pancreas: A single-center experience and review of the literature. *In Vivo (Brooklyn).* 2017 Jul 1;31(4):501–10.
3. Wang W bin, Zhang TP, Sun MQ, Peng Z, Chen G, Zhao YP. Solid pseudopapillary tumor of the pancreas with liver metastasis: Clinical features and management. *European Journal of Surgical Oncology.* 2014;40(11):1572–7.
4. Sibio S, di Carlo S. Current highlights on solid pseudopapillary neoplasm of the pancreas. *World J Hepatol.* 2022 Jan 27 [cited 2022 Dec 6];14(1):300–3.
5. Ranaweera K, Nandasena M, de Silva U, et al. Solid pseudopapillary neoplasm of the pancreas with multiple liver metastases successfully managed with staged resection. *SAGE Open Medical Case Reports.* 2022;10.
6. Yu PF, Hu ZA, Wang XB, Guo JM, Cheng XD, Zhang YL, et al. Solid pseudopapillary tumour of the pancreas: A review of 553 cases in Chinese literature. *World Journal of Gastroenterology.* 2010;16(10):1209.
7. Reindl BA, Lynch DW, Jassim AD. Aggressive variant of a solid pseudopapillary neoplasm: A case report and literature review. *Arch Pathol Lab Med.* 2014;138(7):974–8.



**Figure 3.** Surgical Management of the Tumours