

Intraoperative visualization of biliary anatomy using Indocyanine green (ICG) fluorescence in a Sri Lankan cohort

S.K. Kumarage, D.H.J.P.U. Lakshani, M.D.P. Pinto, P.C. Chandrasinghe
Department of Surgery, Faculty of Medicine, University of Kelaniya, Sri Lanka.

Keywords: Laparoscopic Cholecystectomy (LC), Indocyanine Green (ICG) fluorescence, Bile Duct Injury (BDI), Common Bile Duct (CBD), Biliary anatomy]

Abstract

Introduction

Bile duct injury (BDI) is a complication with high morbidity, associated with laparoscopic cholecystectomy (LC). The risk of BDI can be reduced by accurate visualization of the biliary tree with the use of indocyanine green fluorescence (ICG). This study describes the use of this non-invasive technique in a cohort of Sri Lankan patients to visualize the biliary anatomy intraoperatively.

Method

A total of 121 consecutive patients undergoing LC were included. All received 5 mg of ICG intravenously, 30 minutes prior to induction of anesthesia. The Stryker 1588 laparoscope was used to visualize the anatomical landmarks, both pre and post-dissection of the Calot's triangle, using visible light and near-infrared imaging (NIR).

Result

In 121 patients (female - 64.5%, median age - 42 years; range of 18-82) included in the study, biliary colic was the commonest indication (70%) for LC. ICG fluorescence resulted in significantly better visualization of the extrahepatic biliary tract ($p < 0.001$), both pre-dissection (95%CI = 91.7% [85.3%-96.0%]) and post-dissection (95% CI=71.1% [62.1%-79.0%]) of the Calot's triangle. Furthermore, the hepatic ducts were only visualized with ICG.

Visualization of the Cystic duct common bile duct junction (CDCBDJ) improved from 6% to 88% ($P < 0.001$) pre-dissection with ICG. Fluorescence enabled the visualization of CDCBDJ post-dissection in all cases compared to 54% without it ($P < 0.001$). ICG enhanced visualization of the

Common bile duct (CBD) from 34% to 88% ($P < 0.001$) pre-dissection and 100% visibility post-dissection compared to 62% under visible light ($P < 0.001$). No adverse effects of ICG or bile duct injuries were reported during the study.

Conclusion

The use of ICG during LC significantly enhanced the identification of biliary landmarks in this cohort. Identification of anatomy can help reduce inadvertent BDI. This safe and effective modality may be considered a routine step in LC.

Introduction

LC is a widely performed intra-abdominal surgery on a global scale. In the United States, this procedure alone accounts for 300,000 cases annually [1]. It's a relatively safe and non-invasive procedure compared to open cholecystectomy. However, BDI is a severe complication that can occur during the laparoscopic procedure, with 0.2% to 0.7% incidence. [2]. BDI occurs either due to inadequate visualization or due to anatomical variations in the extrahepatic biliary tree. BDI leads to high morbidity, mortality, and healthcare costs while lowering quality of life. [3,4].

Although several techniques have been developed, such as the infundibular technique and the critical view of safety, BDI has become more frequent with the widespread adoption of LC, which may be due to its absence of tactile sensation and visual misperceptions. Hence, Intraoperative trans-cystic cholangiography was proposed to obtain a clearer view of the biliary tract during LC surgery. However, this procedure requires a specialized catheter and high technical skills to cannulate the cystic duct. Also, the procedure itself could result in BDI if the anatomy is misinterpreted. The benefits of this technique have been extensively debated, and routine use is still not well established [5].

The novel technique, ICG fluorescence cholangiography has been shown to enhance the intraoperative visualization of the anatomy and the blood supply of the biliary tree via excreting ICG into bile, emitting the light when illuminated with NIR mode [6]. This technique is non-invasive, safe, and time-

Correspondence: S.K. Kumarage

E-mail: sumuduk@kln.ac.lk

 <https://orcid.org/0000-0002-5919-4087>

Received: 23-11-2023 Accepted: -06.02.2024

DOI: <http://doi.org/10.4038/sljs.v42i01.9092>



saving and avoids the possibility of bile duct injury associated with the insertion of the cannula during trans-cystic cholangiography [7].

Published data on intraoperative visualization of biliary anatomy using ICG is limited from this region. Furthermore, there is no previously published data from Sri Lanka. This study describes using ICG intraoperatively, evaluating its efficacy in identifying key landmarks and the feasibility of its safe use, in a Sri Lankan patient cohort.

Material and methods

Patients

This is a descriptive analysis of prospectively collected data from 121 consecutive patients who underwent LC. Patients who had LC for biliary colic, acute cholecystitis, chronic

cholecystitis, CBD stones, gall bladder (GB) polyps, and GB cancers were included in the study. Excluded from the study were patients with known iodine allergies, pregnant women, and breastfeeding mothers. Before conducting the study, we ensured that all patients provided informed consent. Additionally, ethical clearance was acquired from the Ethical Review Committee of the Faculty of Medicine at the University of Kelaniya. (P/122/09/2021).

Method

Five milligrams of ICG (Aurogreen®, Aurolab, Madurai) were injected intravenously 30 mins in advance. During the procedure, the patients were closely observed for any possible allergic reaction to the dye. The LC was performed adhering to the recommendations of the Strasburg critical view of safety.

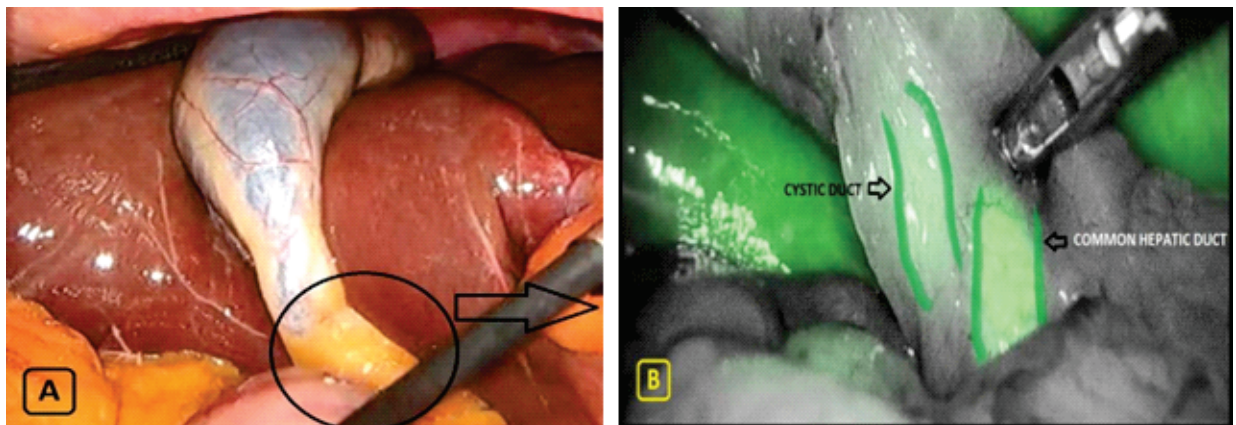


Figure 1. Intraoperative imaging before dissection of the gall bladder; with visible light (A), with NIR mode (B), of the region of interest (marked with a circle) demonstrating the clear-cut differentiation between the cystic duct and the common hepatic duct.

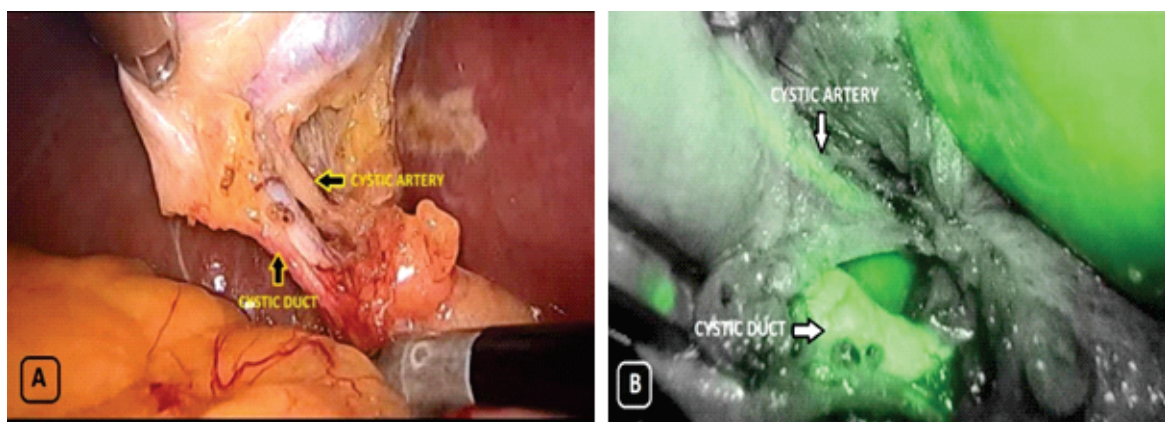


Figure 2. Intraoperative imaging after dissection of the gall bladder; with visible light (A), with NIR mode (B). Note the clear-cut image of the cystic artery and the cystic duct. (Intraoperative administration of a supplemental bolus of ICG was used to enhance real-time visualization of the Cystic artery)

Visualization of the specific anatomical landmarks; cystic duct(CD), CDCBDJ, and important structures; CBD, right hepatic duct (RHD), left hepatic duct (LHD), and common hepatic duct (CHD) was performed using a Stryker 1588 laparoscope, with the visible light and with the NIR mode at the two-time points during the surgery: (1) After exposure of the liver hilum, pre-dissection of Calot's triangle (Figure1), and (2) post-dissection of the Calot's triangle (Figure2). Observations were agreed upon by two surgeons. All procedures were performed and the observations were recorded by the same team led by a surgeon who has performed more than 200 LCs before the study.

Patients were kept under observation following the procedure to detect any adverse effects of ICG or BDI.

Data collection

Patient demographic data were collected during the first consultation. The identification of the specific anatomical landmarks of the biliary tree (CD, CDCBDJ, CBD, RHD, LHD, CHD) at the two time points using the visible light and NIR mode were recorded intraoperatively.

Statistical analysis

The statistical analysis was done using SPSS software version 26. Continuous data is presented as the median value with a 95% confidence interval (CI) for the median, while discrete variables are shown as absolute and relative frequencies. The chi-square (χ^2) test was used to analyze the comparison of a discrete variable. In Cox's stepwise multivariate regression analysis, the associations with a p-value of less than 0.1, as identified in the univariate analysis, were included. Moreover, statistical significance was determined by a two-tailed p-value of less than 0.05.

Results

A total of 121 patients who were treated with LC surgery between January 2019 to September 2021 were included in our study. The median age was 42 years (with a range of 18 to 82) and 64.5% (n=78) were female. Indications for surgery included Biliary colic (n= 84), Acute cholecystitis (n=25), Chronic cholecystitis (n=2), CBD stones (n=5), GB Polyp (3), GB cancer (n=1) and adenomyosis (n=1) (Table 1).

The percentages of extrahepatic biliary tract visualization with ICG versus without ICG fluorescence in the pre-dissection of the calot's triangle are shown in Figure 3. The CDCBDJ visualization was increased from 6% to 87.6% (P<0.001) with ICG whereas CHD visualization increased from 14.9% to 66.1% (p<0.001). The CBD was visualized in

33.9% without ICG in the pre-dissection state was increased up to 87.6%(p<0.001) with ICG fluorescence and the CD from 73.6% to 100% (p<0.001). The hepatic ducts were not visualized without ICG but were visible in 13.2% under ICG fluorescence (p<0.001).

The percentages of extrahepatic biliary tract visualization with ICG compared to without ICG fluorescence in the post-dissection of the Calot's triangle are shown in Figure 4. The CDCBDJ and CBD were visible in all patients after dissection with the use of ICG fluorescence compared to 53.7%, and 62% without it (P< 0.001). The CHD was visualized in 19.8% and was increased up to 91.7% with ICG (P<0.001). The post-dissection visualization of the CD was not affected by using ICG as it was able to visualize in all patients following Calot's triangle dissection.

With ICG fluorescence, the definition of the entire extrahepatic biliary tract (CD+CDCBDJ+CBD+CHD) was possible in 71% of the patient's pre-dissection (4.1% vs 71.1%; 95% CI – 62.1%-79%; P<0.001) and in 91.7% post dissection (15.7% vs 91.7%; 95% CI- 85.3% - 96%; P<0.001) with ICG.

Table 1. Demographic features of the study population.

Characteristics	Frequency(n=121)
Age	
• Mean	43.06
• Median	42.00
• Range	18-82
Sex	
• Male	43(35.5%)
• Female	78(64.5%)
Indication	
• Biliary colic	84(69.4%)
• Acute cholecystitis	25(20.7%)
• Chronic cholecystitis	2(1.7%)
• CBD stones	5(4.1%)
• GB Polyp	3(2.4%)
• GB Cancer	1(0.8%)
• Adenomyosis	1(0.8%)

The CDCBDJ could not be defined pre-dissection under visible light in those with acute cholecystitis. However, the visualization increased to 80% with ICG fluorescence in those “hot gallbladders”. The post-dissection rates for the same increased from 52% to 100%. (Table 2).

No adverse effects of ICG or bile duct injuries were reported during the study and none of the surgeries were converted to Open cholecystectomy.

Discussion

This prospective cohort study, conducted on a cohort of Sri Lankan patients, describes the efficacy and safety of near-infrared imaging with ICG in locating crucial landmarks of

biliary anatomy. The findings reveal that using ICG results in a high rate of visualization of the CD, CBD, CDCBDJ, CHD, RHD, and LHD pre and post-Calot's triangle dissection. Notably, ICG improved the visibility of the CDCBDJ and CBD by 15-fold and 2.5-fold, respectively in pre-dissection, while a 2-fold and 1.6-fold increase was seen respectively post-dissection. Furthermore, the study confirms that hepatic ducts are only visible with ICG. The CDCBDJ is an important landmark to keep away from during LC to prevent BDI. The commonest type of BDI, which is clipping the tented CBD may be prevented if this landmark is visualized [8].

Multiple systemic reviews in the literature have demonstrated that using indocyanine green (ICG) with near-infrared imaging can aid in the safe and non-invasive mapping of the

Table 2. CDCBDJ visualization with the various pathologies of the biliary tract.

NEBD Naked eye before dissection, ICGBD Intracyanine green before dissection, NEAD Naked eye after dissection, ICGAD Intracyanine green after dissection, CDCBDJ Cystic duct common bile duct junction, CBD Common bile duct, GB Gall bladder.

	Biliary colic	Acute cholecystitis	Chronic cholecystitis	CBD stones	GB polyp	GB Cancer	Adenomyosis
NEBD CDCBDJ	4.7%	0%	50%	0%	0%	20%	100%
ICGBD CDCBDJ	90.4%	80%	100%	100%	100%	60%	100%
NEAD CDCBDJ	54.7%	52%	50%	33.3%	100%	66.6%	100%
ICGAD CDCBDJ	100%	100%	100%	100%	100%	100%	100%

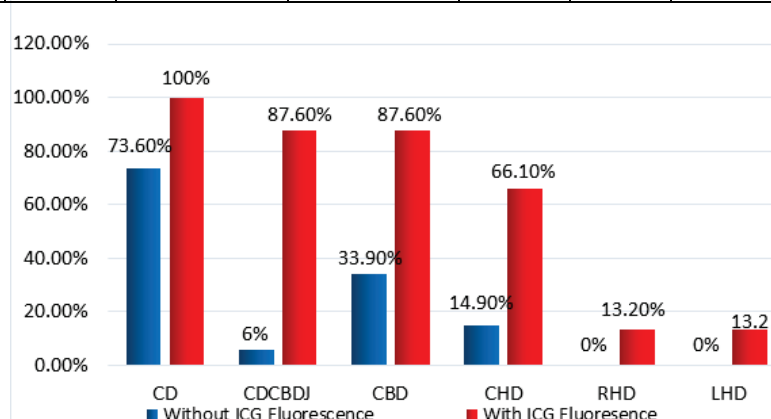


Figure 3. Biliary tract visualization before dissection. ICG Intracyanine green, CD Cystic duct, CDCBDJ Cystic duct common bile duct junction, CBD Common bile duct, CHD Common hepatic duct, RHD Right hepatic duct, LHD Left hepatic duct.

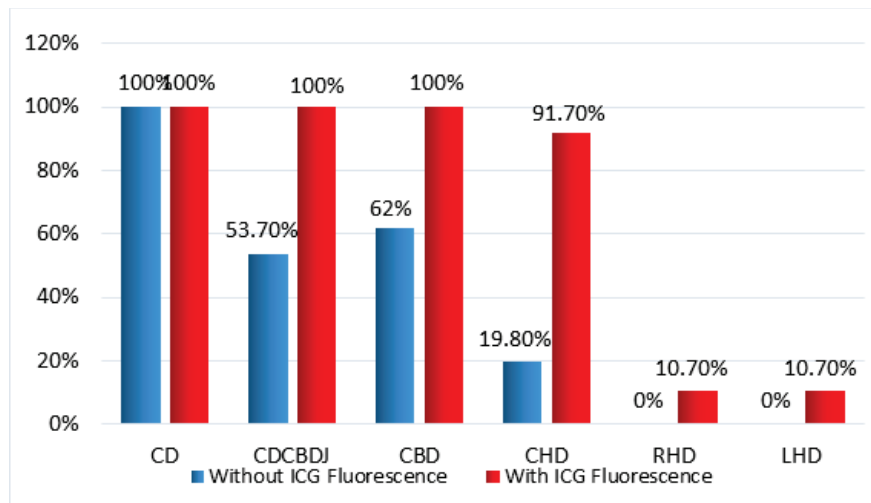


Figure 4. Biliary tract visualization after dissection. ICG Intracyanine green, CD Cystic duct, CDCBDJ Cystic duct common bile duct junction, CBD Common bile duct, CHD Common hepatic duct, RHD Right hepatic duct, LHD Left hepatic duct.

biliary tree anatomy during LC [9,10]. ICG is an injectable dye that is water-soluble and binds to proteins in plasma after injection. It is a substance that is exclusively metabolized in the parenchymal cells of the liver and gets excreted into the bile, where the peak concentration of the ICG in the bile occurs between 30 minutes to 2 hours and in the arterial system, it occurs only within 1–2 minutes. It is stimulated by near-infrared light providing fluorescent visualization of vascular and biliary structures [6].

In this study, a standard dosage of 5mg of ICG was administered intravenously 30 minutes before anesthesia. While several studies have attempted to achieve the highest bile duct-liver ratio of fluorescence, there is still no definitive conclusion on the most effective timing and dosage of ICG administration. Most Previous studies have administered ICG within 30-60 minutes before the procedure, using varying dosages. Some studies have used a fixed 1.25-7.5mg of diluted ICG solution [11,12], while others have used an adjusted 0.02-0.62mg/kg dose [13,14].

Our research suggests that using ICG can result in high visualization rates of CD, CBD, and CHD structures, with 100%, 87%, and 66% respectively. Bleszynsky et al analyzed 108 cases and reported visualization rates of 90%, 84%, and 48% for CD, CBD, and CHD structures, respectively [15]. Similarly, Dip Fernando et al conducted a study on 45 cases and found visualization rates of 97.7%, 80%, and 60% for CD, CBD, and CHD structures, respectively [16]. Even though differences in dosages and timing of ICG administration, as well as variances in investigators and study

populations, these results are comparable with the current study.

Hepatic ducts (RHD, LHD) are relatively deeper biliary structures and are more difficult to visualize even with the fluorescence evidenced by 0% to 13% in pre- and 0% to 10% in post-dissection, with ICG. However, when compared to the traditional techniques ICG fluorescence enables to visualization of those structures is an added advantage in hepatobiliary surgeries [17].

As the penetration rates vary with the degree of inflammation, the status of the local inflammation is one of the most important sources of bias that we encountered during the analysis of the final results. According to the literature, ICG improves the visualization of complicated pathologies in the biliary tract [15,18]. Similarly, in our cohort, 80% of acute cholecystitis patients showed a definition of the CDCBDJ only possible with ICG, potentially facilitating early laparoscopic cholecystectomy (LC). This could result in advantageous outcomes for both the patient and healthcare system alike.

The BDI rate, adverse effects of ICG, and conversion to open cholecystectomy rates are 0% in our study. However, one of the major limitations of this study is its small sample size. Since bile duct injury and conversion to open cholecystectomy are low-frequency complications, the limited number of cases makes it difficult to fully comprehend the issue. Furthermore, this study did not offer evidence that ICG fluorescence reduces BDI. A randomized

control trial with a larger sample size is necessary to verify this. However, we have demonstrated that the extrahepatic biliary tract anatomy visualization is enhanced with the ICG. It is quite rational to assume that if the anatomy is visualized and defined, the chances of injuring inadvertent BDI will be reduced.

Conclusion

The use of ICG intraoperatively during the LC has been shown to significantly enhance the definition of the extrahepatic biliary tract during LC. Its routine use may have the potential to reduce BDI through better visualization of the biliary anatomy but needs to be tested in a future well-powered randomized trial.

References

1. Hassler KR, Collins JT, Philip K, Jones MW. Laparoscopic Cholecystectomy. 2023 Jan 23. In: StatPearls [Internet]. Treasure Island (FL): StatPearls Publishing; 2023 Jan-. PMID: 28846328.
2. Flum DR, Dellinger EP, Cheadle A, Chan L, Koepsell T. Intraoperative cholangiography and risk of common bile duct injury during cholecystectomy. *JAMA*. 2003;289(13):1639-1644. doi:10.1001/jama.289.13.1639.
3. Booij KAC, De Reuver PR, Van Dieren S, Van Delden OM, Rauws EA, Busch OR, et al. Long-term Impact of Bile Duct Injury on Morbidity, Mortality, Quality of Life, and Work Related Limitations. *Ann Surg*. 2018 Jul;268(1):143-150. doi: 10.1097/SLA.0000000000002258.
4. Fong ZV, Pitt HA, Strasberg SM, Loehrer AP, Sicklick JK, Talamini MA, et al; California Cholecystectomy Group. Diminished Survival in Patients with Bile Leak and Ductal Injury: Management Strategy and Outcomes. *J Am Coll Surg*. 2018 Apr;226(4):568-576.e1. doi: 10.1016/j.jamcollsurg.2017.12.023.
5. Ausania F, Holmes LR, Ausania F, Iype S, Ricci P, White SA. Intraoperative cholangiography in the laparoscopic cholecystectomy era: why are we still debating? *Surg Endosc*. 2012 May;26(5):1193-200. doi: 10.1007/s00464-012-2241-4.
6. Alander JT, Kaartinen I, Laakso A, Pätälä T, Spillmann T, Tuchin VV, et al. A review of indocyanine green fluorescent imaging in surgery. *Int J Biomed Imaging*. 2012;2012:940585. doi: 10.1155/2012/940585.
7. Quaresima S, Balla A, Palmieri L, Seitaj A, Fingerhut A, Ursi P, et al. Routine near infra-red indocyanine green fluorescent cholangiography versus intraoperative cholangiography during laparoscopic cholecystectomy: a case-matched comparison. *Surg Endosc*. 2020 May;34(5):1959-1967. doi: 10.1007/s00464-019-06970-0.
8. de'Angelis N, Catena F, Memeo R, Coccolini F, Martínez-Pérez A, Romeo OM, et al. 2020 WSES guidelines for the detection and management of bile duct injury during cholecystectomy. *World J Emerg Surg* 16, 30 (2021). doi:10.1186/s13017-021-00369-w.
9. Vlek SL, Van Dam DA, Rubinstein SM, De Lange-de Klerk ESM, Schoonmade LJ, Tuynman JB, et al. Biliary tract visualization using near-infrared imaging with indocyanine green during laparoscopic cholecystectomy: results of a systematic review. *Surg Endosc*. 2017 Jul;31(7):2731-2742. doi: 10.1007/s00464-016-5318-7.
10. Serban D, Badiu DC, Davitoiu D, Tanasescu C, Tudosie MS, Sabau AD, et al. Systematic review of the role of indocyanine green near-infrared fluorescence in safe laparoscopic cholecystectomy (Review). *Exp Ther Med*. 2022 Feb;23(2):187. doi: 10.3892/etm.2021.11110.
11. Boogerd LSF, Handgraaf HJM, Huurman VAL, Lam HD, Meio JSD, Van der Made WJ, et al. The Best Approach for Laparoscopic Fluorescence Cholangiography: Overview of the Literature and Optimization of Dose and Dosing Time. *Surgical Innovation*. 2017 Aug;24(4):386-396. doi: 10.1177/1553350617702311.
12. Daskalaki D, Fernandes E, Wang X, Bianco FM, Elli EF, Ayloo S, et al. Indocyanine green (ICG) fluorescent cholangiography during robotic cholecystectomy: results of 184 consecutive cases in a single institution. *Surg Innov*. 2014 Dec;21(6):615-21. doi: 10.1177/1553350614524839.
13. Dip F, LoMenzo E, Sarotto L, Phillips E, Todeschini H, Nahmod M, et al. Randomized Trial of Near-infrared Incisionless Fluorescent Cholangiography. *Ann Surg*. 2019 Dec;270(6):992-999. doi: 10.1097/SLA.0000000000003178.
14. Agnus V, Pesce A, Boni L, Van Den Bos J, Morales-Conde S, Paganini AM, et al. Fluorescence-based cholangiography: preliminary results from the IHU-IRCAD-EAES EURO-FIGS registry. *Surg Endosc*. 2020 Sep;34(9):3888-3896. doi: 10.1007/s00464-019-07157-3.
15. Bleszynski MS, DeGirolamo KM, Meneghetti AT, Chiu CJ, Panton ON. Fluorescent Cholangiography in Laparoscopic Cholecystectomy: An Updated Canadian Experience. *Surg Innov*. 2020 Feb;27(1):38-43. doi: 10.1177/1553350619885792.
16. Dip F, Roy M, Lo Menzo E, Simpfendorfer C, Szomstein S, Rosenthal RJ. Routine use of fluorescent incisionless cholangiography as a new imaging modality during laparoscopic cholecystectomy. *Surg Endosc*. 2015 Jun;29(6):1621-6. doi: 10.1007/s00464-014-3853-7.
17. Ishizawa T, Saiura A, Kokudo N. Clinical application of indocyanine green-fluorescence imaging during hepatectomy. *Hepatobiliary Surg Nutr*. 2016 Aug;5(4):322-8. doi:10.21037/hbsn.2015.10.01.

18. Ankersmit M, Van Dam DA, Van Rijswijk AS, Van den Heuvel B, Tuijnman JB, Meijerink WJHJ. Fluorescent Imaging With Indocyanine Green During Laparoscopic Cholecystectomy in Patients at Increased Risk of Bile Duct Injury. *Surg Innov.* 2017 Jun;24(3):245-252. doi:10.1177/1553350617690309.