

Anatomical relations of the recurrent laryngeal nerve in thyroid dissection.

V. Abeysuriya, S.A.P.D. Anjula

¹Faculty of Medicine, University of Kelaniya, Sri Lanka

Keywords: recurrent laryngeal nerve, inferior thyroid artery, suspensory ligament of berry, inferior horn of the thyroid cartilage, Anatomical variants

Abstract

Introduction

Recurrent laryngeal nerve (RLN) palsy is one of the major complications thyroidectomy. Visualization of the anatomical relations of the RLN with branches of the inferior thyroid artery (ITA) remains essential for preservation of RLNs. Suspensory ligament of Berry, inferior horn of the thyroid cartilage is considered as other important landmarks for safe thyroidectomy. The objective of this study was to describe the various anatomical relations of the RLN during thyroid dissection.

Methods

An observation cadaveric study was conducted by simple random sampling of 35 cadavers with a total of 70 RLNs over a one-year period, from June 2022 to June 2023. The cadavers that had thyroidotomies and goitres were excluded from the study

Results

The majority of RLNs in this series had a retrovascular course (with respect to the ITA or its branches): 57% on the right and 68.6% on the left. The course of 64/70 of the dissected nerves was posteromedial to the suspensory ligament of Berry, while the other 6 nerves passed between the fibres of this ligament. All RLNs penetrated the larynx by passing posteriorly to the inferior horn of the thyroid cartilage on both sides. No case of non-recurrent laryngeal nerve was observed.

Conclusion

This preliminary study illustrates the numerous anatomical variants of the RLN with respect to the ITA and its branches. The RLN mainly has a retrovascular course on both the right

and the left sides.

Introduction

Thyroidectomy is one of the most commonly performed surgeries in neck [1] One of the major complications of this surgery is recurrent laryngeal nerve (RLN) palsy.[2,3] A comprehensive knowledge of the anatomy of the thyroid region is essential to avoid iatrogenic RLN injuries. It has now been clearly established that visualization of the RLN remains the main factor of preservation of nerve and to reduce incidence of postoperative recurrent laryngeal nerve palsy.[4-6]

Visualization of the anatomical relations of the recurrent laryngeal nerve with branches of the inferior thyroid artery (ITA) is vital for preservation of recurrent laryngeal nerve. Suspensory ligament of berry and inferior horn of the thyroid cartilage are considered as other anatomical relations of recurrent laryngeal nerve. [1-6] The objective of this study was to describe the various anatomical relations of the RLN during thyroid dissection.

Methods


An observation cadaveric study was conducted by simple random sampling of 35 cadavers with a total of 70 RLNs over a one-year period, from June 2022 to June 2023. The cadavers that had thyroidotomies and goitres were excluded from the study

Dissection technique

Kocher neck incision made and the superior and inferior platysma skin flaps were created and the thyroid gland was exposed. Lateral surface of the lobe was dissected while observing the presence of middle thyroid vein. Dissection of the inferior pole was done, and the inferior thyroid veins were ligated. ligation of the superior vascular pedicle was done as close as possible to the superior pole. The method of identification of the RLN was lateral approach, the various anatomical relations of the recurrent laryngeal nerve especially with the ITA, variations of the course of the RLN, the presence of any extra laryngeal divisions and the presence of a non-recurrent laryngeal nerve were observed. The ethical

Correspondence: V. Abeysuriya

E-mail: vasithaabey@hotmail.com

 <https://orcid.org/0000-0002-0986-7917>

Received: 07-07-2023 Accepted: 07-11-2023

DOI: <http://doi.org/10.4038/sljs.v41i03.9071>



clearance was obtained. No conflict of interest.

Statistical analysis

Data analysis was performed with Statistical Package for Social Sciences (SPSS) version 19.0. Data were expressed as frequencies.

Results

A total of 35 cadavers were included in this study (28 F: 7 M). A total of 70 recurrent laryngeal nerves were identified. Seventeen right RLNs crossed the trunk of the ITA, mostly posteriorly;(7 anteriorly and 10 posteriorly). The majority of left recurrent laryngeal nerves did not cross the trunk of the ITA (23/35). (Table 01)

Considering the anatomical relations of the right RLNs with branches of the ITA, 35 of the right RLNs dissected, the majority of nerves (17/35) crossed anterior to the branches of the ITA and 5/35 RLNs traversed between the branches of the ITA. (Table 01) On the left side, 18/35 traversed anterior to the branches of the ITA, 14 RLNs passed posterior to the branches of the ITA and 3 RLNs were between branches of the ITA. The majority of RLNs in our study had a posterior relation with the trunk or branches of the ITA, 57.14% on the right and 68.57% on the left. (Table 01)

Table: 1: Anatomical relations to the RLN

	Right side	Left side
Number of RLNs that cross the ITA trunk	17/35	12/35
Number of RLNs that cross the ITA trunk anteriorly	7/35	2/35
Number of RLNs that cross the ITA posteriorly	10/35	10/35
Number of RLNs that cross the branches of ITA anteriorly.	17/35	18/35
Number of RLNs that cross the branches of ITA posteriorly.	10/35	14/35
Number of RLNs that passes between the branches of ITA	5/35	3/35
Number of RLNs located posteromedial to the suspensory ligament of berry	32/35	32/35
Number of RLNs penetrated into the larynx by passing posteriorly to the inferior horn of the thyroid cartilage	35/35	35/35
Number of non RLNs identified	0/35	0/35

The course of 64/70 of the dissected nerves was posteromedial to the suspensory ligament of Berry, while the other 6 nerves passed between the fibres of this ligament. All RLNs penetrated into the larynx by passing posteriorly to the inferior horn of the thyroid cartilage on both sides.

No case of non-recurrent laryngeal nerve was observed in our series.

Discussion

There are several approaches can be used to identify RLN. We lateral approach in our series. The anatomical relations between the RLN and ITA constitute a classical landmark for recurrent laryngeal nerve identification. Its main landmark is the inferior thyroid artery (ITA) at the middle or lower third of the posterolateral surface of the thyroid lobe and identification of the recurrent laryngeal nerve in the middle third of the lateral lobe.[7-15]

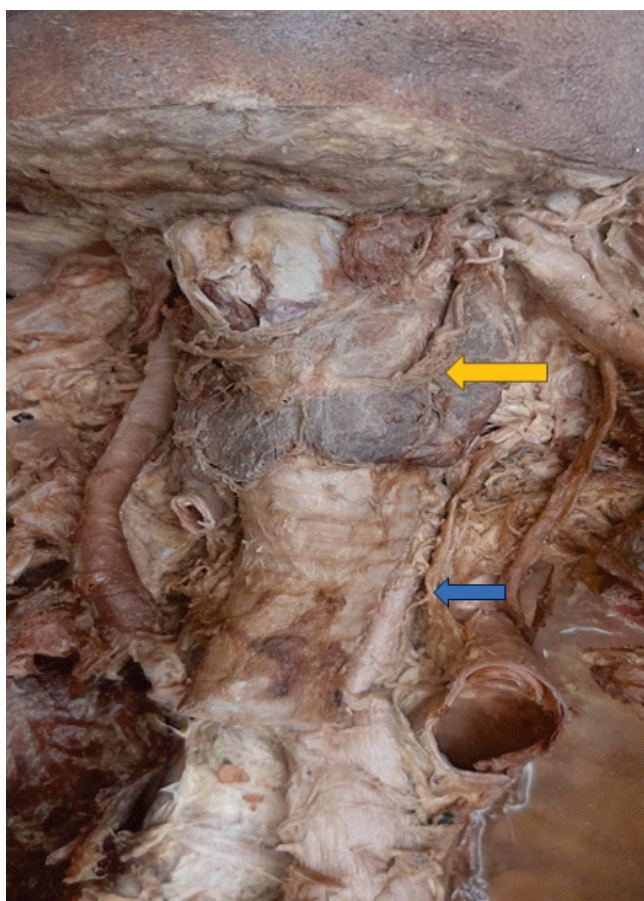


Figure 1: Thyroid gland (yellow arrow) and Left Recurrent laryngeal nerve (blue arrow).

In our study of 70 dissected nerves, the relations between the RLN and the ITA essentially concerned especially branches of the ITA), with a predominantly retrovascular course (57.14% on the right and 68.57% on the left). These results are like those of operative series reported [7,12,13,16]. However, the various relations of the RLN with the ITA observed in our series did not show any predominant differences according to the side. We observed a considerable percentage of RLNs passing between branches of the ITA (transvascular course, 14.28% on the right and 8.57% on the left). According to some literature, this transvascular pattern is predominant and would increase risk of intraoperative injury. [7,17,18] Even though numerous positions of the RLN in relation to the ITA have been described, [12,13,18] most literature stated that the classical location of the RLN would be anterior to the ITA on the right and posterior to the ITA on the left in more than 50% of cases [15,16]

The suspensory ligament of Berry is an important landmark of the course of the RLN before it enters the larynx. In our study, 91.43% of RLNs had a posteromedial course with respect to this ligament and 8.57% of nerves crossed the fibres of this ligament. These findings agree with the data of the literature. [14-19]

In this study, all recurrent laryngeal nerves penetrated the larynx by passing posteriorly to the inferior horn of the thyroid cartilage. The inferior horn of the thyroid cartilage, considered in the literature to be the most reliable landmark of the recurrent laryngeal nerve, indicates the point of entry of the nerve into the larynx. [8,10,20]. No case of non-recurrent laryngeal nerve was observed in our series. This anatomical anomaly remains rare, representing less than 1% of cases in many series [12,17,21] It is usually observed on the right, except in patients with situs inversus, with a retro-tracheo-oesophageal course of the left subclavian artery.[12,17,21] Even though, multiple extra laryngeal divisions are reported in the literature, with rates ranging between 24 and 70%. [12, 21] No multiple extra laryngeal divisions of the RLNs were observed in our study. This cadaveric study explores the anatomical relationship of the recurrent laryngeal nerve with the inferior thyroid artery and the ligament of Berry. The study shows that the course of both the right and left RLNs is primarily retrovascular, which differs slightly from what is published in the literature. [12,17,21] Thus, the results could be of interest to anatomists and surgeons.

Conclusion

This study showed anatomical variants of the RLN with respect to the trunk of the ITA and its branches. The RLN

mainly has a retrovascular course on both the right and the left sides.

References

1. Ndjolo A, Eposse EC, Bob Oyono JM, Fouda OA, Bengono G. ENT surgical practice in an African environment: an evaluation of five and a half years in the hospitals of Yaoundé. *Black African medicine*. 2006;53(1):29-33.
2. Conessa CL, Sissokho B, Faye M. Complications of thyroid surgery at the Principal Hospital of Dakar: About 155 interventions. *Black African medicine*. 2000;47(3):157-60.
3. Procaccianti F, Diamantini G, Caciolo F, Abilalaj V. Visual identification of the recurrent laryngeal nerve during thyroidectomy. *Ann Ital Chir* 2011;82(4):261–5.
4. Dralle H, Sekulla C, Lorenz K, Brauckhoff M, Machens A, German IONM Study Group. Intraoperative monitoring of the recurrent laryngeal nerve in thyroid surgery. *World journal of surgery*. 2008 Jul; 32:1358-66.
5. Gavilán J, Gavilán C. Recurrent laryngeal nerve: identification during thyroid and parathyroid surgery. *Archives of Otolaryngology–Head & Neck Surgery*. 1986 Dec 1;112(12):1286-8.
6. Périé S, Aït-Mansour A, Devos M, Sonji G, Baujat B, St Guily JL. Value of recurrent laryngeal nerve monitoring in the operative strategy during total thyroidectomy and parathyroidectomy. *European annals of otorhinolaryngology, head and neck diseases*. 2013 Jun 1;130(3):131-6.
7. Koumaré AK, Ongoiba N, Sissoko F, Berete S, Diop AT, Sidibé Y, Doumbia D, Coulibaly Y, Sidibé-Traoré A, Dembélé M, Mohamed AA. Inferior laryngeal nerve: anatomy and operative lesions. *e-memoirs of the National Academy of Surgery*. 2002;1(2):8-11.
8. Page C, Peltier J, Charlet L, Laude M, Strunski V. Superior approach to the inferior laryngeal nerve in thyroid surgery: anatomy, surgical technique and indications. *Surgical and Radiologic Anatomy*. 2006 Dec; 28:631-6.
9. Loré J. Practical anatomical considerations in thyroid tumor surgery. *Arch Otolaryngol*. 1983;109(9):568-74.
10. Makeieff M, Guerrier B. Retrograde dissection of the recurrent nerve in thyroid surgery. *Fr ENT*. 2006; 90:203-9.
11. Kulekci M, Batoglu-Karaaltın A, Saatci O, Uzun I. Relationship between the branches of the recurrent laryngeal nerve and the inferior thyroid artery. *Annals of Otolaryngology, Rhinology & Laryngology*. 2012 Oct;121(10):650-6.
12. Sturniolo G, D'Alia C, Tonante A, Gagliano E, Taranto F, Schiavo MG. The recurrent laryngeal nerve related to thyroid surgery. *The American journal of surgery*. 1999 Jun 1;177(6):485-488.
13. Campos BA, Henriques PR. Relationship between the

recurrent laryngeal nerve and the inferior thyroid artery: a study in corpses. *Revista do Hospital das Clínicas*. 2000; 55:195-200.

14. Lee MS, Lee UY, Lee JH, Han SH. Relative direction and position of recurrent laryngeal nerve for anatomical configuration. *Surgical and radiologic anatomy*. 2009 Nov; 31:649-55.

15. Lee MS, Lee UY, Lee JH, Han SH. Relative direction and position of recurrent laryngeal nerve for anatomical configuration. *Surgical and radiologic anatomy*. 2009 Nov; 31:649-55.

16. Tang WJ, Sun SQ, Wang XL, Sun YX, Huang HX. An applied anatomical study on the ² laryngeal nerve and inferior thyroid artery. *Surgical and radiologic anatomy*. 2012 May; 34:325-32.

17. Uen YH, Chen TH, Shyu JF, Shyr YM, Su CH, Chen JY, Lee CS, Liu JC. anatomy of the recurrent laryngeal nerves and its clinical applications in Chinese adults. *Surgery today*. 2006 Apr; 36:312-5.

18. Monfared A, Gorti G, Kim D. Microsurgical anatomy of the laryngeal nerves as related to thyroid surgery. *The Laryngoscope*. 2002 Feb; 112(2):386-92.

19. Moreau S, De Ruy MG, Babin E, Salame E, Delmas P, Valdazo A. The recurrent laryngeal nerve: related vascular anatomy. *The Laryngoscope*. 1998 Sep; 108(9):1351-3.

20. Wang C. The use of the inferior horn of the thyroid cartilage in the identification of the recurrent laryngeal nerve. *Surg Gynecol Obstet*. 1975; 140(1):91-4.

21. Yalcin B, Tunali S, Ozan H. Extralaryngeal division of the recurrent laryngeal nerve: a new description for the inferior laryngeal nerve. *Surg Radiol Anat* 2008; 30:215–20.