

Research

Open Access

A long-term investigation of the anti-hepatocarcinogenic potential of an indigenous medicine comprised of *Nigella sativa*, *Hemidesmus indicus* and *Smilax glabra*

SS Iddamaldeniya¹, MI Thabrew*², SMDN Wickramasinghe¹, N Ratnatunge³ and MG Thammitiyagodage⁴

Address: ¹Department of Biochemistry, Faculty of Medicine, University of Sri Jayawardenepura, Gangodawila, Nugegoda, Sri Lanka, ²Department of Biochemistry and Clinical Chemistry, Faculty of Medicine, University of Kelaniya, 6, Thalagolla Road, Ragama, Sri Lanka, ³Department of Pathology, Faculty of Medicine, University of Peradeniya, Peradeniya, Sri Lanka and ⁴Animal Centre, Medical Research Institute, Colombo 08, Sri Lanka

Email: SS Iddamaldeniya - amalr@slt.net.lk; MI Thabrew* - mrthab@dynamweb.lk; SMDN Wickramasinghe - nalinie@sjp.ac.lk; N Ratnatunge - neela72002@yahoo.com; MG Thammitiyagodage - mayurithammitiyagodage@yahoo.com

* Corresponding author

Published: 09 May 2006

Received: 19 June 2005

Journal of Carcinogenesis 2006, 5:11 doi:10.1186/1477-3163-5-11

Accepted: 09 May 2006

This article is available from: <http://www.carcinogenesis.com/content/5/1/11>

© 2006 Iddamaldeniya et al; licensee BioMed Central Ltd.

This is an Open Access article distributed under the terms of the Creative Commons Attribution License (<http://creativecommons.org/licenses/by/2.0>), which permits unrestricted use, distribution, and reproduction in any medium, provided the original work is properly cited.

Abstract

Background: A decoction comprised of *Nigella sativa* seeds, *Hemidesmus indicus* root bark and *Smilax glabra* rhizome is being recommended for cancer patients by a family of traditional medical practitioners of Sri Lanka. Previous investigations have demonstrated that a short term (10 weeks) treatment with the decoction can significantly inhibit diethylnitrosamine (DEN) mediated expression of Glutathione S-transferase P form (GST-P) in rat liver. The objective of the present investigation was to determine whether long term (16 months) treatment with the decoction would be successful in inhibiting in rat livers, not only DEN-mediated expression of GST-P, but also the carcinogen mediated development of overt tumours (OT) or histopathological changes leading to tumour development (HT).

Methods: Thirty-six male Wistar rats were divided into 3 groups of 12 each. Groups 1 and 2 were injected intraperitoneally (i.p) with DEN (200 mg/kg) while group 3 was injected normal saline (NS). Twenty-four hours later, decoction (DC; 6 g/kg body weight/day) was orally administered to group 1 rats, while groups 2 and 3 (DEN-control and normal control) were given distilled water (DW). Treatment with DC or DW continued for 16 months. At the end of the 9th month and 16th months (study 1 and study 2 respectively), six rats from each group were sacrificed, and livers observed for OT or HT, both visually and by subjecting liver sections to staining with Haematoxylin and Eosin (H & E), Sweet's Silver stain (for reticulin fibers), Periodic Acid Schiff (PAS) staining (for glycogen), and immunohistochemical staining (for GST-P).

Results: At the end of 9 months (study 1) a hepatocellular adenoma (HA) developed in one of the rats in the DEN + DW treated group (group 2). At the end of 16 months (study 2), livers of all rats of group 2 developed OT and HT. Large areas of GST-P positive foci were also observed. No OT, HT or GST-P positive foci were detected in any of the other groups.

Conclusion: Protection against DEN-mediated carcinogenic changes in rat liver can be achieved by long term treatment with the DC comprised of *N. sativa* seeds, *S. glabra* rhizome and *H. indicus* root bark.

Background

Traditional and Ayurvedic Physicians in Sri Lanka use several plant-based remedies for treatment of cancer with varying degrees of success. However, until recently, none of these preparations have been subjected to any form of scientifically controlled investigation to determine their efficacy as curative or palliate agents against cancer. A herbal remedy prescribed to cancer patients by the Jayathilake family of Ayurvedic physicians (personal communication, Ayurvedic Dr. Nimal Jayathilake) is a decoction (DC) prepared from *Nigella sativa* seeds, *Hemidesmus indicus* root and *Smilax glabra* rhizome. A recent investigation by Iddamaldeniya *et al* [1] demonstrated that short-term (10 weeks) treatment of rats with the DC can protect their livers against DEN-mediated expression of the P-isoform of Glutathione S-transferase (GST-P). The objective of the present study was to determine the long-term anti-hepatocarcinogenic effects of the DC. This was achieved by assessing the ability of the DC to inhibit diethylnitrosamine (DEN)-mediated expression of GST-P, as well as the development of overt tumours (OT) and histopathological changes leading to tumour development (HT), in livers of rats treated with the carcinogen.

Methods

Experimental animals

In all experiments Wistar rats (8 week old littermates, 190 ± 10 g) purchased from the Medical Research Institute, Sri Lanka (MRI), were used and maintained in a temperature controlled room (25°C ± 12°C) under 12 hours light/dark cycle (dark phase 6 p.m. to 6 a.m.). The Wistar strain that originated from the Wistar Institute of Biology, USA and introduced into CLEA, Japan were introduced to the Animal House, MRI, Sri Lanka in 1990.

Rats were fed with a standard laboratory diet containing 19% crude proteins, 3.8% fibre and 4400 kcal of energy, prepared by the Medical Research Institute, Sri Lanka, based on a formula recommended by the WHO, and water *ad libitum* [2]. The feed was prepared from ingredients purchased from several companies. Thus, Maize meal, Milk powder, Wheat flour and Mollasses were purchased from Ceylon Grain Elevators, Ceylon Milk Foods, Ceylon Wholesale Establishment, and Sugar factory, Hingurana, Sri Lanka, respectively. Fish Meal (Danish 999) was imported by the MRI, directly from Denmark. All other ingredients were supplied by S. V.K. and Sons, Colombo, Sri Lanka.

Plant material

Dried rhizome of *Smilax glabra*, dried seed of *Nigella sativa* and dried root of *Hemidesmus indicus* were purchased locally from Nandana Ayurveda Drug Suppliers, Maharagama, Sri Lanka and identities were confirmed by the Botanist (Mr. Gunarathne Silva), Bandaranayake Memorial

Ayurveda Research Institute, Navinna, Maharagama, Sri Lanka. A single batch of dried plant material purchased initially was used throughout the experimental period, to avoid batch- to-batch variations.

Chemicals

Diethylnitrosamine (DEN) and Diaminobenzidine (DAB) were purchased from Sigma Diagnostics Inc. USA Normal Swine serum, Rabbit polyclonal anti GST -P antibody, Biotin labeled anti Rabbit IgG and Avidin Biotin-peroxidase Complex (ABC) were purchased from DAKO, Denmark. All other chemicals were purchased from Sigma Chemicals, USA.

Preparation of the decoction

The plant decoction was prepared according to the method recommended traditionally for administration to cancer patients (information provided by Dr. N. Jayathilake, Bandaranayake Memorial Ayurvedic Research Institute, Navinna, Maharagama, Sri Lanka.)

Twenty grams each of *Nigella sativa* (seeds), *Hemidesmus indicus* (root) and *Smilax glabra* (rhizome) were mixed and boiled in 1.6 l of distilled water and the final volume was reduced to 200 ml by boiling over 3 hours.

Dosage and administration of decoction

The decoction was administered at a dose of 6 g/kg/day to rats using a Sondi needle by gastric gavage method. This dose was used in all experiments, as it proved to be the most effective dose in the short term study conducted previously [1].

Ethical approval

Ethical approval for the study was granted by the Ethical Committee of the University of Sri Jayawardenapura, Sri Lanka.

Experimental procedure

Thirty-six Wistar rats were randomly divided into 3 groups of 12 each. Groups 1 and 2 were injected with DEN (200 mg/kg) to initiate hepatocarcinogenesis [3] while group 3 was given normal saline (NS) i.p. Twenty-four hours later the DC (6 g/kg body weight/day) was orally administered to group 1 rats, while groups 2 and 3 were given same volume (3 ml) of distilled water (DW). Oral feeding continued for two weeks after which all rats were subjected to 2/3 partial hepatectomy (PH) by the technique recommended by Higgins and Anderson [4], to promote hepatocarcinogenesis. On the following day, oral feeding was resumed and continued for a total of 16 months. At end of the 9th months (study 1) and 16th month (study 2), six rats from each group respectively, were sacrificed and livers examined for OT and tumour like lesions (TL). Samples of livers were also excised and processed for

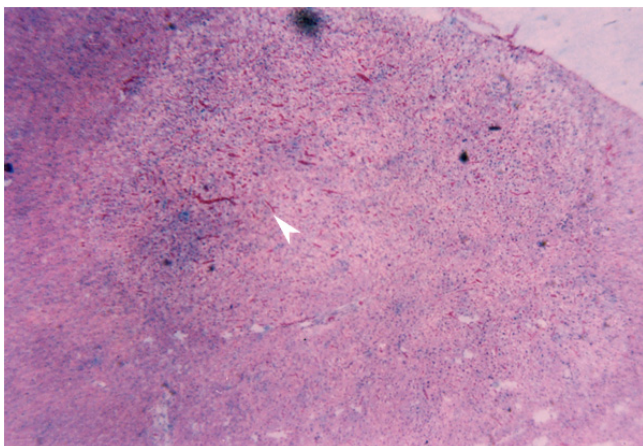


Figure 1
Hepatocellular Adenoma 9 months after DEN + DW treatment. H & E staining ($\times 4$)

assessment of DEN-mediated histopathological changes related to hepatocarcinogenesis (HT) as well as GST-P expression.

Tissue processing and staining

At autopsy, livers were excised from all animals, and slices of 2–3 mm thick (six slices of liver, two each from the right posterior, right anterior and caudate lobes) were cut with a surgical blade, fixed in 10% phosphate buffered formalin. The samples were processed using a tissue processor and embedded in paraffin. Paraffin blocks were cut using a micro tome cutter. Three sets of the liver sections from study 1 were subjected to Haematoxylin and Eosin (H & E) staining, Silver staining for reticulin fibers, and Immunohistochemical staining for Glutathione S-trans-

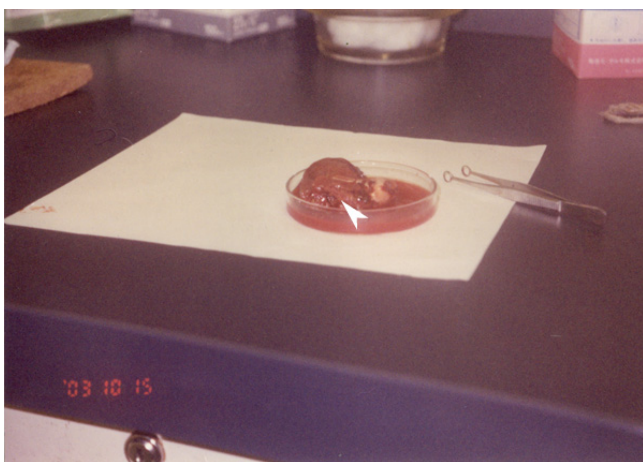

Figure 2
Hepatocellular carcinoma 16 months after DEN + DW treatment.

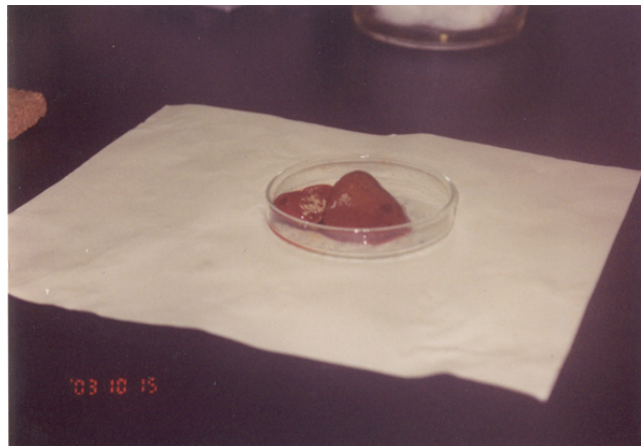


Figure 3
A liver from the group which received DEN + DC for 16 months.

ferase P form (GST-P). Sections from rats in study 2 were stained with all the above stains, as well as the Periodic Acid Schiff (PAS) stain (with and without Diastase) for detection of glycogen.

The method described by Alan and Ian [5] was employed in making H & E stained sections. The Silver staining method described by Gorden and Sweet [6] was employed to stain reticulin fibres in liver sections, while PAS staining was conducted according to the method described by McManus [7].

GST-P immunohistochemistry

The Avidin Biotin peroxidase Complex (ABC) method described by Hsu *et al* [8] was used to demonstrate GST-P liver foci. Deparaffinized sections were treated with normal swine serum (1:10), rabbit polyclonal anti GST-P antibody (1:150), biotin labeled anti rabbit IgG (1:300) and ABC. The sites of peroxidase binding were visualized using Diaminobenzidine (DAB). Sections were counter stained with Carazzi's Haematoxylin for microscopic examination. As positive control for the specificity of anti-GST-P antibody binding human thyroid sections were used. The number of foci and number of cells/cm² were measured using an OLYMPUS research microscope ($\times 400$). The final numbers for each parameter were computed after microscopic examination of the whole area of each section.

The above parameters were quantified in the prepared liver sections by Prof. N. Ratnatunge (pathologist Faculty of Medicine, University of Peradeniya, Sri Lanka), who was blind to the identities of the samples.

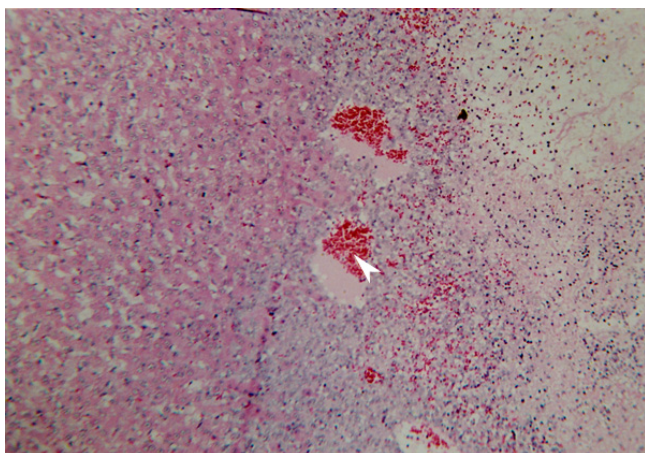


Figure 4
Liver section from group 2 (DEN + DW), H & E, (×10).

Statistical analysis

The results are expressed as Mean ± Standard Error of Mean (S.E.M). The significance of difference in the number of GST-P positive foci between the control and test groups were analyzed by the Student's t-test.

Results

On examination of rat livers at the end of 9 months, a hepatocellular adenoma was observed in only one of the rats in group 2 (DEN + DW) (Fig 1). However, by the end of the 16th month, overt tumours (OT) or tumour like lesions (TL) were observed visually (Fig. 2) in livers of all rats in this group. In contrast, no OT or TL were observed in the post-mortem, in either rats from this group 1 (DEN+ DC) or group 3 (NS + DW), even at the end of 16 months (Fig. 3), although the livers of group 1 animals appeared to be hyper plastic, with some adhesions.

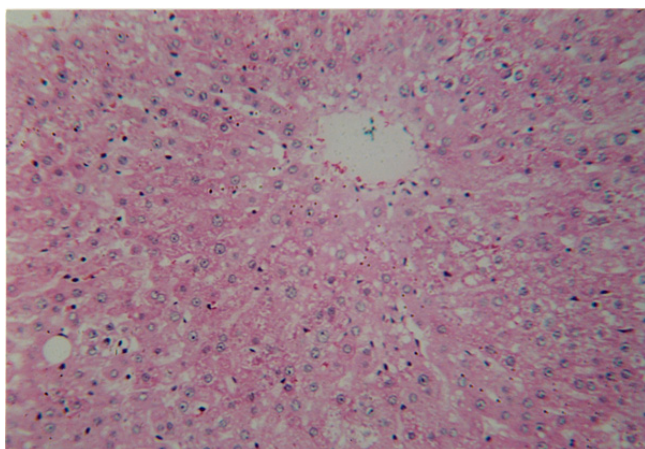


Figure 5
Liver section from group 1 (DEN + DC), H & E, (×10).

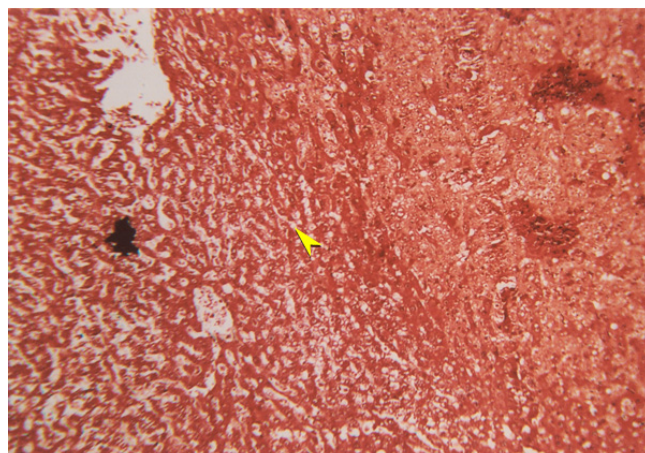


Figure 6
Sweet's Silver staining of group 2 liver section (×40).

H & E staining revealed in all rats of group 3 (NS + DW), the typical architecture expected of normal livers, even at the end of 16 months. On the other hand, H & E staining of livers of group 2 rats (DEN + DW) at the end of 9 months, revealed severe and diffused granular degeneration and cell swelling; At the end of 16 months, growing hepatocellular carcinomas were evident in livers of all rats in this group (Fig.4). One of the most notable features observed in livers of this group, was the extensive angiogenesis. Although a mild to moderate degree of granular and vacuolar degeneration were observed in livers of group 1 (DEN + DC) rats at the end of 16 months, the degree of such degenerative changes, as well as angiogenesis in livers of this group, were of much less intensity than those seen in group 2 rats (Fig. 5).

As expected, silver staining revealed a normal black stained reticulin framework in livers of group 3 rats (NS +

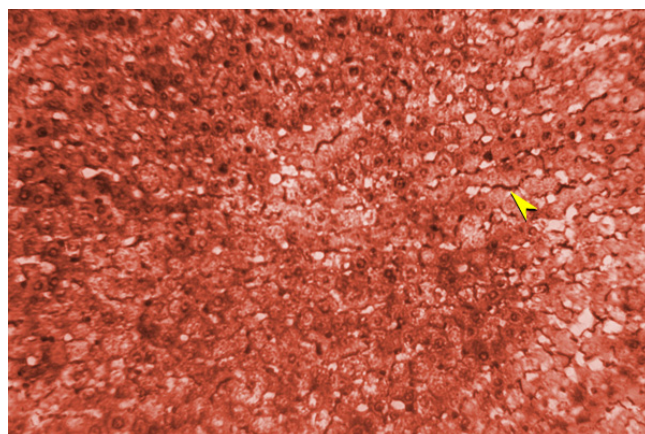


Figure 7
Sweet's Silver staining of group 1 liver section (×40).

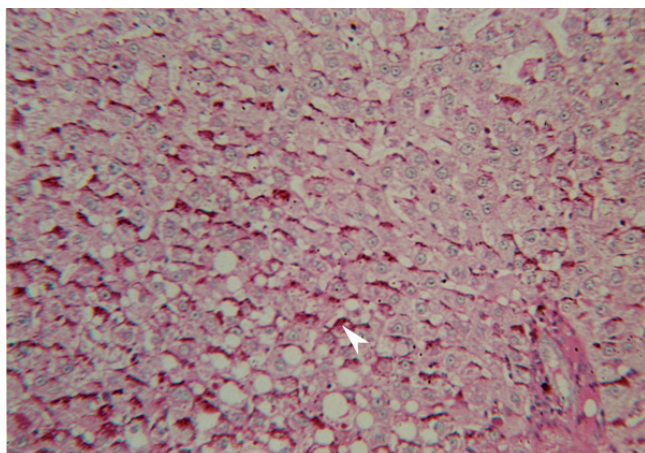


Figure 8
PAS staining with diastase, group 2 (×40).

DW) throughout the experimental period. However, in group 2 (DEN + DW) animals, silver staining revealed disruption of the reticulin framework, as evident from the reduction in staining intensity in some areas. At the end of 16 months, a severe reduction of the reticulin framework was observed in rats of this group, as demonstrated by the virtual absence of silver stained reticulin fibres in the liver sections (Fig. 6). In contrast, in group 1 (DEN + DC) animals, at the end of 16 months of DC treatment, a return of the reticular framework towards normal was observed (Fig. 7).

Further support for the development of hepatocellular carcinomas in group 2 (DEN + DW) rats, was obtained by

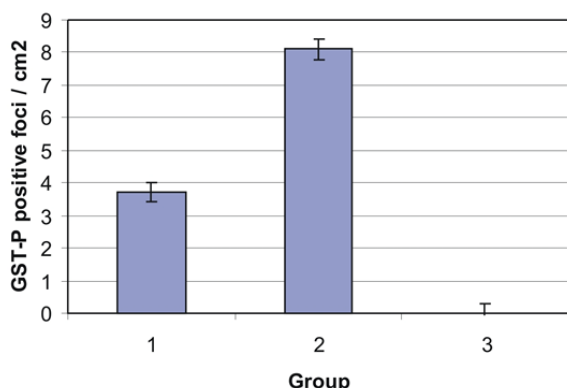


Figure 9
Effects of a decoction treatment for 16 months on number of DEN-mediated GST-P positive foci in Wistar rats. Group 1: DEN + Decoction. Group 2: DEN + Distilled water. Group 3: Normal saline + Distilled water

PAS staining. Thus, in these animals, positive staining of similar intensity was observed in liver sections exposed to this stain, both with and without diastase (Fig. 8). However, in livers of group 1 rats (DEN + DC), PAS staining without diastase was positive while PAS staining with diastase was negative.

As demonstrated in the previous short-term investigation by Iddamaldeniya *et al* [1], immunohistochemical staining revealed large areas of GST-P positive foci in livers of groups 2 rats (DEN +DW), but not in rats of group 3 (NS + DW). In group 1 rats (DEN + DC), in comparison to livers of group 2 (DEN + DW) animals, there was a significant reduction ($P < 0.05$) in the number of GST-P positive foci (Fig 9).

Discussion

An increasing number of investigations are being conducted worldwide, to discover natural products that can suppress or prevent the process of carcinogenesis [9-12] and [13]. Research on plants have not only confirmed the presence of potential anticancer components in many plants used traditionally for the treatment of cancer, but also helped in the identification of compounds with anticancer activity from non-traditionally used plants, that have subsequently been developed into clinically useful drugs [14] and [15].

A recent short-term study by Iddamaldeniya *et al.* [1], has shown that diethylnitrosamine (DEN)-induced expression of the p-isoform of glutathione S-transferase (GST-P) in rat livers could be significantly inhibited by treatment of rats for 10 weeks, with the decoction (DC) comprised of *N.sativa* seeds, *H.indicus* roots, and *S. glabra* rhizome, that has also been used in the present investigation. From results obtained, it was concluded that the DC has the potential to protect against chemically-induced hepatocarcinogenesis. Results of the present investigation provide further supportive evidence for this view. Thus, long-term treatment (for up to 16 months) of rats with the DC has been demonstrated to inhibit not only DEN-induced GST-P expression, but also the carcinogen-mediated development of overt tumours (OT) and histopathological changes leading to tumour development (HT) as assessed both by visual observations and by microscopic examination of liver sections stained with H&E, Sweet's silver stain and the PAS stain for glycogen. The above stains have been used by many other researchers to assess histopathological changes associated with liver tumour development [16,17] and [18].

One of the most notable features observed in livers of rats treated only with DEN, was the extensive angiogenesis associated with carcinogen-mediated tumours and tumour-like lesions. In rats treated with DEN and the DC,

a marked reduction of angiogenesis was observed. Inhibition of angiogenesis is generally considered to be one method by which tumour growth can be inhibited or reversed [19-21] and [14]. Recent investigations have shown that inhibition of angiogenesis is a mechanism by which many phytochemicals also mediate their anti-cancer effects [22-26] and [27]. The anti-angiogenic effects of these natural products have been shown to be related to their abilities to reduce inflammation and/or vascular permeability, or production of detrimental eicosanoids and other angiogenic factors [28]. The mechanism/s by which the DC comprised of *N. sativa*, *H. indicus* and *S. glabra* inhibits angiogenesis are not clear, although each of the above plants have been reported to possess strong anti-inflammatory properties [29-31] and [32]. Further studies have to be conducted before any definite conclusions can be reached regarding the mechanism/s by which the DC mediates anti-angiogenic effects.

Previous investigations have shown that *N. sativa* seeds and *H. indicus* root contain components with strong anti-oxidant activity [33-35] and [36]. All three of the plants in the DC have also been shown to possess immunomodulatory properties [37-40] and [33]. These properties may also contribute to the antihepatocarcinogenic actions of the DC.

Recent in-vivo studies have shown that active principles isolated from *N. sativa* seeds and an *H. indicus* root extract can inhibit tumour development in mouse skin [41] and [42]. Principles isolated from *N. sativa* seeds [41,43] and [39] and *S. glabra* rhizome [44] has also been demonstrated to be cytotoxic to several human cancer cell lines. At present, it is not possible to be certain whether only one of the plants in the DC is mainly responsible for mediating the observed anti-hepatocarcinogenic effects or whether all three plants contribute to different extents. Studies currently being conducted in our laboratory with extracts of the individual plants in the DC, would hopefully in the near future, yield results that would help to clarify these doubts.

Abbreviations

DEN: Diethylnitrosamine

GST-P: Glutathione S-transferase P-isoform

DAB: Diaminobenzidine

ABC: Avidin Biotin-peroxidase Complex

PH: Partial-Hepatectomy

S.E.M: Standard Error of Mean

OT: Overt Tumours

TL: Tumour like Lesions

HT: Histopathological changes leading to development of tumours

DC: Decoction

DW: Distilled Water

NS: Normal Saline

i.p: Intraperitoneally

PAS: Periodic Acid Schiff

Authors' contributions

SSI did feed preparation, animal handling and feeding under the supervision of MGT. SSI and MGT participated in the surgical procedure for partial hepatectomy. SSI under the supervision of NR performed the immunohistochemical and histopathological staining processes and the interpretation of the stained sections. IT, NW and SSI conceived, designed the study and IT coordinated it. IT and SSI participated in writing the manuscript.

Acknowledgements

We thankfully acknowledge the research grant from National Science Foundation, Sri Lanka and Dr. N. Jayathilake for providing the recipe for preparation of the decoction. Authors also wish to thank Dr. S. Jayasekara and Mr. Sarath Sisira Kumara, Animal Centre, MRI, Colombo and Ms. Sujatha Ramadasa, Faculty of Medicine, Department of Pathology, University of Peradeniya, Peradeniya for the support provided.

References

- Iddamaldeniya SS, Wickramasinghe N, Thabrew I, Ratnatunge N, Thammitiyagodage M: **Protection against diethylnitrosamine induced hepatocarcinogenesis by an indigenous medicine comprised of *Nigella sativa*, *Hemidesmus indicus*, and *Smilax glabra*: A preliminary study.** *J Carcinogenesis* 2003, **2**:6-11.
- Sabourdy MA: *Breeding and Care of laboratory animals Volume 1*. WHO Health Laboratory Technology Unit, Geneva, Switzerland; 1988:18-19.
- Ito N, Tsuda H, Hasagawa R, Imaida K: **Sequential observation of pathomorphologic alterations in preneoplastic lesions during the promoting stage of hepatocarcinogenesis and the development of short-term system for hepatopromoters and hepatocarcinogens.** *Toxicology and Pathology* 1982, **10**:37-49.
- Higgins GM, Anderson RM: **Experimental pathology of the liver: Restoration of the liver of the white rat following partial surgical removal.** *Archives of Pathology* 1931, **12**:186-202.
- Alan S, Ian W: **The haematoxylin and eosin.** In *theory and practice of histological techniques* Edited by: John DB, Alan S. Whitehall Books Ltd, Wellington, New Zealand; 1996:212-9.
- Gordon H, Sweet HH: **A simple method for the Silver impregnation of reticulum.** *American Journal of Pathology* 1936, **12**:545.
- McManus JFA: **Histological demonstration of mucin after periodic acid.** *Nature* 1946, **158**:202.
- Hsu SM, Rain L, Fanger H: **Use of avidin-biotin-peroxidase complex (ABC) in immunoperoxidase techniques, a comparison between ABC and unlabeled antibody (PAP) procedures.** *Journal of Histochemistry and Cytochemistry* 1981, **29**:577-80.

9. Manthey JA, Guthrie N: **Antiproliferative activities of citrus flavonoids against six human cancer cell lines.** *J Agric Fd Chem* 2002, **50**:5837-5843.
10. Lee SMY, Li MLY, Tse Yc, Fung KP, Lee CY, Wway MMY: **Paeoniae Radix a Chinese herbal extract inhibits hepatoma cells growth by inducing apoptosis in a p-53 independent pathway.** *Life Sci* 2002, **71**:2267-2277.
11. Aggarwal BB, Kumara A, Barti AC: **Anticancer potential of curcumin: pre-clinical and clinical studies.** *Anticancer Res* 2003, **23**:363-398.
12. Chen JJ, Ye ZQ, Koo MW: **Growth inhibition and cell cycle arrest effects of epigallocatechin gallate in the NBT-II bladder tumour cell line.** *BJU Int* 2004, **93**:1082-1086.
13. Cheng YL, Change WL, Lee SC, Liu YG, Chen CJ, Lin SZ, Tsai NM, Yu DS, Yeu CY, Harn HJ: **Acetone extract of *Anjelica sinensis* inhibits proliferation of human cancer cells via inducing cell cycle arrest and apoptosis.** *Life Sci* 2004, **75**:1579-1594.
14. Boik J: *Natural Compounds in Cancer Chemotherapy* Oregon Medical Press, Minnesota, USA; 2002.
15. Kinghorn AD, su BN, Jang DS, Chang LC, Lee D, Gu JQ, Cercache-Blanco EJ, Pawlus AD, Lee SK, Park EJ, Cuendet M, Gills JJ, Bhat K, Park HS, Mata-Greenwood E, Song LL, Jang M, Pezzuto JM: **Natural inhibitors of Carcinogenesis.** *Planta Medica* 2004, **70**:691-705.
16. Varma V, Cohen C: **Immunohistochemical and molecular markers in the diagnosis of hepatocellular carcinoma.** *Adv Anat Pathol* 2004, **11**:239-49.
17. Miyao Y, Ozaki D, Nagao T, Kondo Y: **Interstitial invasion of well-differentiated hepatocellular carcinoma and subsequent tumor growth.** *Pathol Int* 1999, **49**:208-13.
18. Altaf FJ: **Hepatocellular carcinoma.** *Saudi Med J* 2001, **22**:416-8.
19. Majewski S, Marczak M, Szmurlo A: **Retinoids, interferon alpha, I, 25-dihydroxy vitamin D₃, and their combination inhibit angiogenesis induced by non-HPV-harboring tumour cell lines. RAR alpha mediates the antiangiogenic effect of retinoids.** *Cancer Lett* 1995, **89**:117-124.
20. Kerbel RS: **Tumour angiogenesis: Past, present, and near future.** *Carcinogenesis* 2000, **21**:505-515.
21. Brewer GJ, Dick RD, Grover DK: **Treatment of metastatic cancer with tetrathiomolybdate, and anti copper angiogenic agent: Phase I study.** *Clinical Cancer Research* 2000, **6**:1-10.
22. Gao C, ding Z, Wiang B, Chen N, Chen D: **Study on the effects of curcumin on angiogenesis.** *Zhong Yao Cai* 2003, **26**:499-502.
23. Hornick CA, Myers A, Sadowska -Krowicka H, Antony CT, Wohterong EA: **Inhibition of angiogenesis initiation and development of newly established human vascular networks by juice of *Morinda citrifolia* (noni).** *Angiogenesis* 2003, **6**:143-149.
24. Kimura Y, Tamigulu M, Baba K: **Anti-tumours and anti-metastatic activities of 4-hydroxy derricin isolated from *Angelica keiskei* roots.** *Planta Medica* 2004, **70**:211-219.
25. Singh RP, Aggarwal R: **Prostate cancer prevention by Silibinin.** *Current Cancer Drug Targets* 2004, **4**:1-11.
26. Singh RP, Tyagi AK, Dhanalakshmi S, Aggarwal R, Aggaewal C: **Grape seed extract inhibit advanced human prostate growth and angiogenesis and up-regulated insulin like growth factor binding protein-3.** *International J of Cancer* 2004, **108**:733-740.
27. Hahm ER, Gho YS, Park s, Park C, Kim KW, Yang CH: **Synthetic curcumin analogues inhibit activator protein -I transcription and tumour induced angiogenesis.** *Biochemical and Biophysical communications* 2004, **321**:337-344.
28. Aggarwal BB, Bhardwaj A, Aggarwal RS, Seeram NP, Shishodia S, Takada Y: **Role of resveratrol in prevention and therapy of cancer: preclinical and clinical studies.** *Anticancer Res* 2004, **24**:2783-840.
29. Jiang JY, Wu FH, Lu JF, Lu ZH, Xu QN: **Anti-inflammatory activities of aqueous extracts from rhizome *Smilax glabra*.** *Pharmacol Res* 1997, **36**:309-314.
30. Houghton PJ, Zarka R, de las Heras B, Hoult JRS: **Fixed oil of *Nigella sativa* and derived thymoquinone inhibit eicosanoid generation in leukocytes and membrane lipid peroxidation.** *Planta Med* 1995, **61**:33-36.
31. Alam MI, Gomes A: **Viper venom induced inflammation and inhibition of free radical formation by pure compound (2-hydroxy-4-methoxybenzoic acid isolated and purified from ananthamul (*Hemidesmus indicus*) root extract.** *Toxicol* 1998, **36**:207-215.
32. Al-Ghamdi MS: **The anti-inflammatory, analgesic and antipyretic activity of *Nigella sativa*.** *J Ethnopharmacol* 2001, **76**:45-48.
33. Alam MI, Gomes A: **Adjuvant effects of an antiserum action potentiation by a (herbal) compound 2-hydroxy-4-methoxy benzoic acid isolated from the root extract of the Indian medicinal plant "sarsaparilla" (*Hemidesmus indicus*).** *Toxicol* 1998, **36**:1423-1431.
34. Burtis M, Bucar F: **Antioxidant activity of *Nigella sativa* essential oil.** *Phytother Res* 2000, **14**:323-328.
35. Ravishankaran MN, Shrivasthava N, Padh H, Rajani M: **Evaluation of antioxidant properties of root bark of *Hemidesmus indicus* R. Br. (anathamul).** *Phytomedicine* 2002, **9**:153-160.
36. Ali BH, Blunden G: **Pharmacological and Toxicological properties of *Nigella sativa*.** *Phytotherapy Res* 2003, **17**:299-305.
37. El-Kadi A, Kandil O, Tabuni AM: ***Nigella sativa* cell-mediated immunity.** *Arch AIDS Res* 1987, **1**:232-233.
38. Haq A, Lobo P, Al-Tufail M, Rama N, Al-sedairy ST: **Immunomodulatory effect of *Nigella sativa* proteins fractioned by ion exchange chromatography.** *Int J Immunopharmacol* 1999, **21**:283-295.
39. Swamy SMK, Tan BKH: **Cytotoxic and immunopotentiating effects of ethanolic extract of *Nigella sativa* L. seeds.** *J Ethnopharmacol* 2000, **70**:1-7.
40. Chen T, Li J, Cao J, xu Q, Komatsu K, Namba T: **A new flavonone isolated from rhizome *Smilaxis glabrae* and the structural requirements of its derivatives for preventing immunological hepatocyte damage.** *Planta Medica* 1999, **65**:56-59.
41. Salomi NJ, Nair SC, Jayawardhanan KK, Varghese CD, Panikkar LR: **Anti-tumour principles from *Nigella sativa* and saffron (*Crocus sativus*) on chemical carcinogenesis.** *Cancer Lett* 1992, **63**:41-46.
42. Sultana S, Khan N, Sharma S, Alam A: **Modulation of biochemical parameters by *Hemidesmus indicus* in cumene hydroperoxide-induced murine skin carcinoma: possible role in protection against free radical -induced cutaneous oxidative stress and tumour promotion.** *Journal of Ethnopharmacology* 2003, **85**:33-41.
43. Worthen DR, Ghosheh O, Crooks PA: **The *in vitro* anti-tumour activity of some crude and purified components of black seed, *Nigella sativa*.** *Anticancer Res* 1998, **18**:1527-1532.
44. Itharat A, Houghton PJ, Eno-amooquaye E, Burks RJ, Sampson JH, Raman A: ***In-vitro* cytotoxic activity of Thai medicinal plants used traditionally to treat cancer.** *J Ethnopharmacol* 2004, **90**:33-38.

Publish with **BioMed Central** and every scientist can read your work free of charge

"BioMed Central will be the most significant development for disseminating the results of biomedical research in our lifetime."

Sir Paul Nurse, Cancer Research UK

Your research papers will be:

- available free of charge to the entire biomedical community
- peer reviewed and published immediately upon acceptance
- cited in PubMed and archived on PubMed Central
- yours — you keep the copyright

Submit your manuscript here:
http://www.biomedcentral.com/info/publishing_adv.asp



BioMed Central publishes under the *Creative Commons Attribution License (CCAL)*. Under the *CCAL*, authors retain copyright to the article but users are allowed to download, reprint, distribute and /or copy articles in BioMed Central journals, as long as the original work is properly cited.